

## PATIENT

Daisy Behr

## SPECIES

Canine

## BREED

German Shorthaired  
Pointer

## SEX

Spayed Female

## AGE

2 Years

## WEIGHT

20.3 kg

## INTERPRETED BY

Heike Rudorf, DVM, Dr.  
med. Vet., DipECVDD  
DVR

## IMAGING PERFORMED BY

Bo

## HOSPITAL NAME

Green Dog Dental and  
Wellness

## REFERRING VET

Dr. Michael Geist

## INVOICE

36631

## DATE

4/17/26

## PRESENTING CLINICAL SIGNS

History: Acute vomiting - r/o gastric foreign material, dietary indiscretion, intestinal obstruction

## RADIOGRAPHIC STUDY OF THE ABDOMEN

The body condition score is 5/9 with little s.c. fat.

The bony structures are within normal limits.

The abdominal organs are partially surrounded by little fat; diaphragm and abdominal wall are intact.

The liver is located within the costal arch, and the caudo-ventral lobe is pointed.

The tail of the spleen appears large, with clear cut edges.

The stomach is moderately distended with air and food. Distribution and size of the small intestinal loops appear physiological. Colon and rectum contain a small amount of formed fecal matter.

The left renal shadow has a physiological size, shape and opacity. The right is obscured by intestinal loops. The bladder is located intraabdominally and contains a small amount of fluid.

An ovoid, soft tissue opacity is located between bladder neck and Os pubis.

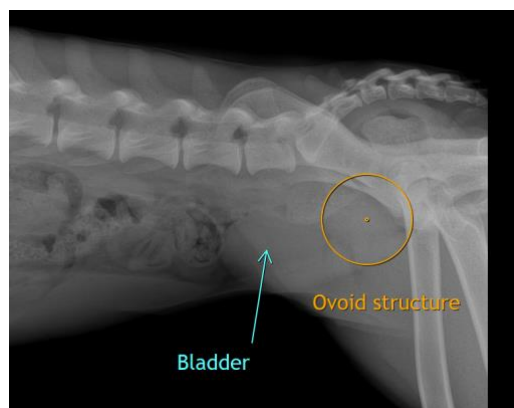
The sublumbar region appears physiological.

## RADIOGRAPHIC DIAGNOSIS

- Possible uterine stump enlargement

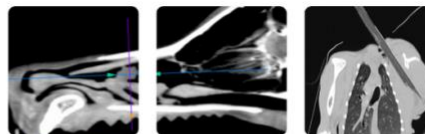
## INTERPRETATION OF THE FINDINGS & FURTHER RECOMMENDATIONS

I can see no gastro-intestinal changes that would explain the vomiting. Abdominal ultrasound is recommended to look for an enlargement of the uterine stump to rule out granuloma, cyst and pyometra. Gastro-intestinal thickness and layering as well as the pancreas should be examined if the caudal abdomen does not reveal a pathology. Biochemistry should then include cPLi, B12 and folate.



**The information and recommendations provided are based on the images presented by the referring veterinarian/sonographer. No evaluation can be communicated regarding pathology that was not visible in the image/video clips provided.**

Thank you for this referral. If the clinical or image interpretation does not parallel your findings or if I



**PATIENT**

Daisy Behr

**SPECIES**

Canine

**BREED**

German Shorthaired  
Pointer

**SEX**

Spayed Female

**AGE**

2 Years

**WEIGHT**

20.3 kg

**INTERPRETED BY**

Heike Rudorf, DVM, Dr.  
med. Vet., DipECVDI  
DVR

**IMAGING  
PERFORMED BY**

Bo

**HOSPITAL NAME**

Green Dog Dental and  
Wellness

**REFERRING VET**

Dr. Michael Geist

**INVOICE**

36631

**DATE**

4/17/26

can be of any further assistance, please contact me.

**Heike Rudorf**, DVM, Dr. med. vet., DipECVDI, DVR  
[info@sonopath.com](mailto:info@sonopath.com)