



PATIENT PRESENTING CLINICAL SIGNS

Ozzie Kingsley History: Owner concerned about new mass, would like to have them surgically removed, has had MCT previous. Met check

SPECIES Abnormal PE/Chem/CBC/UA Results: Met check

Canine

RADIOGRAPHIC STUDY OF THE THORAX AND ABDOMEN

The body condition score is 7/9 with smooth alternating layers of fat and soft tissue opacity. New bone is evident on the stifle joints. Smooth new bone bridges the LS junction ventrally and is present on the endplates of T13/L1.

BREED

Boxer

Thorax

SEX

The degree of pulmonary expansion is fair at best. The lungs are in contact with the thoracic boundaries and the tips are pointed. The lobar vessels are visible.

Neutered Male

The cranial mediastinum is of physiological size and opacity. The trachea diverges from the thoracic vertebrae and the carina is located at T5.

AGE

10

Abdomen

The abdominal detail is good; diaphragm and abdominal wall are intact.

INTERPRETED BY

The liver is located within the costal arch and the caudo-ventral lobe is pointed.

Heike Rudolf, DVM,
Dr. med. Vet.,
DipECVDI DVR

Most of the tail of the spleen is located within the costal arch.

The stomach contains some air, the axis runs parallel to the ribs. Distribution and size of the small intestinal loops appear physiological. The colon contains a small amount of fecal matter.

HOSPITAL NAME

Northshore VH

Both renal shadows have a physiological size, shape and opacity. The bladder is located in the abdominal cavity and contains a moderate amount of homogeneous fluid opacity.

The sublumbar region appears physiological.

REFERRING VET

Brita Kifney

RADIOGRAPHIC DIAGNOSIS

- I can see no obvious metastases

Incidental findings

INVOICE

22011

- Mild stifle arthrosis
- TL and LS spondylosis

INTERPRETATION OF THE FINDINGS & FURTHER RECOMMENDATIONS

DATE

4/14/23



PATIENT

Ozzie Kingsley

The region of the left atrium (LA) appears prominent but this is likely due to the combination of expiration and the amount of pericardial fat. The abdominal organs have, apparently, already been ultrasonographically assessed. The regional lymph nodes should be identified and can be sampled if the new mass also turns out to be malignant.

SPECIES

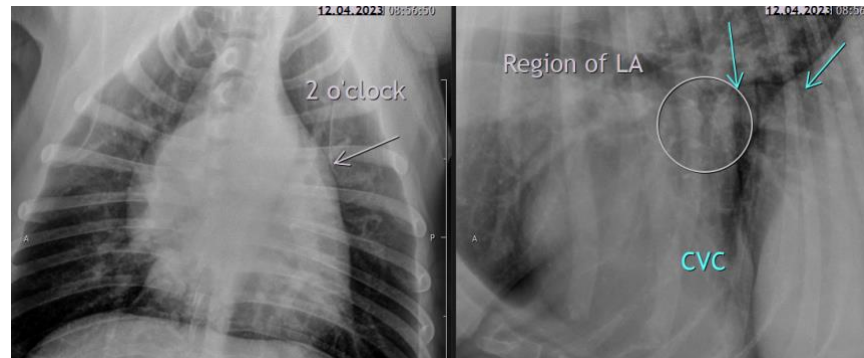
Canine

BREED

Boxer

SEX

Neutered Male



The information and recommendations provided are based on the images presented by the referring veterinarian/sonographer. No evaluation can be communicated regarding pathology that was not visible in the image/video clips provided.

AGE

10

Thank you for this referral. If the clinical or image interpretation does not parallel your findings or if I can be of any further assistance please contact me.

Heike Rudorf, DVM, Dr. med. vet., DipECVDI, DVR
dr.h.rudorf@gmail.com

INTERPRETED BY

Heike Rudorf, DVM,
Dr. med. Vet.,
DipECVDI DVR

HOSPITAL NAME

Northshore VH

REFERRING VET

Brita Kifney

INVOICE

22011

DATE

4/14/23