



PATIENT PRESENTING CLINICAL SIGNS

Moochy Jones History: Coughing for a week
Abnormal PE/Chem/CBC/UA Results: BW unremarkable, PE unremarkable, BCS 7/9

SPECIES RADIOGRAPHIC STUDY OF THE THORAX

Feline The body condition score is 8/9 with smooth alternating layers of fat and soft tissue opacity. A generous amount of fat surrounds the abdominal organs and the kidneys.

The bony structures appear physiological. On the VD right and left ribs run horizontal.

BREED

DSH The degree of pulmonary expansion is fair at best. The lungs are in contact with the thoracic boundaries and the tips are pointed. The lobar vessels are clearly visible to the tertiary branches. On the VD view the bronchi for the caudal lobes are highlighted and the walls appear slightly thickened.

SEX

Neutered Male The cranial mediastinum occupies the cranial thorax to rib 3 on the lateral views. On the VD view it has a physiological expansion and size. is of physiological size and opacity. The trachea diverges slightly from the thoracic vertebrae and the carina is located at T5.

AGE

12 Years The cardiac silhouette occupies 75% of the chest height and 2.5 intercostal spaces. No chamber or outflow tract enlargement is evident.
Thin lines of calcium outline the renal pelvis on both sides.

RADIOGRAPHIC DIAGNOSIS

INTERPRETED BY

- Mild bronchial pattern
- Reduced pulmonary expansion
- Obesity
- Calcified renal pelvis, bilateral (incidental findings)

Heike Rudolf, DVM,
Dr. med. Vet.,
DipECVDI DVR

INTERPRETATION OF THE FINDINGS & FURTHER RECOMMENDATIONS

HOSPITAL NAME

Reduction of the space occupied by the lungs is likely due to the obesity which is known to worsen clinical signs of cough and impair lung function; weight control is strongly recommended.

St. Catherines AH

REFERRING VET

The caudal lobar bronchi appear altered but this may be caused by the reduced inflation. Bronchitis can be present without obvious radiographic evidence and thus bronchoscopy with broncho-alveolar lavage is necessary to rule out infection and inflammation. General anesthesia also allows assessment of the upper respiratory tract in case enlarged tonsils or a nasopharyngeal polyp are present.

Dr. Jui Gokhale

Calcium deposits in the renal pelvis can result in uroliths or sludge in the bladder and further investigations (e.g. urinalysis) are recommended when clinical signs occur.

INVOICE

22009

DATE

4/14/23



PATIENT

Moochy Jones

SPECIES

Feline

BREED

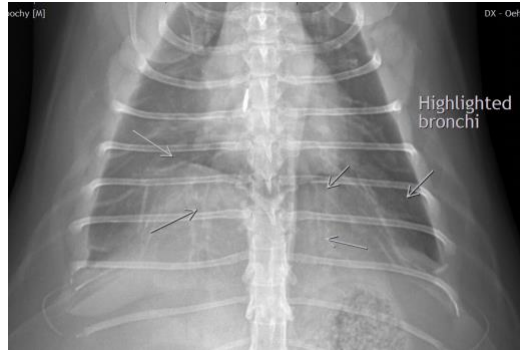
DSH

SEX

Neutered Male

AGE

12 Years



The information and recommendations provided are based on the images presented by the referring veterinarian/sonographer. No evaluation can be communicated regarding pathology that was not visible in the image/video clips provided.

Thank you for this referral. If the clinical or image interpretation does not parallel your findings or if I can be of any further assistance please contact me.

Heike Rudolf, DVM, Dr. med. vet., DipECVDI, DVR
dr.h.rudorf@gmail.com

INTERPRETED BY

Heike Rudolf, DVM,
Dr. med. Vet.,
DipECVDI DVR

HOSPITAL NAME

St. Catherines AH

REFERRING VET

Dr. Jui Gokhale

INVOICE

22009

DATE

4/14/23