



## PATIENT

Mr. Meow Aiken

## SPECIES

Feline

## BREED

DSH

## SEX

Neutered Male

## AGE

15

## WEIGHT

13.8

## INTERPRETED BY

Heike Rudorf, DVM, Dr.  
med. Vet., DipECVDI  
DVR

## IMAGING PERFORMED BY

Dr. Christopher Dewitt

## HOSPITAL NAME

Williamsburg VC

## REFERRING VET

Dr. Christopher Dewitt

## INVOICE

36543

## DATE

4/10/26

## PRESENTING CLINICAL SIGNS

History: Patient presents with hyperthyroidism. An exam was done for patient to get items checked off for radiocat (rads, bloodwork, blood pressure etc).

## RADIOGRAPHIC STUDY OF THE THORAX

The body condition score is 7/9. A soft tissue nodule is located to the left of ribs 7/8 and ventral to the elongated xiphisternum.

Bridging spondylosis is located ventral to C6/7.

The cranial mediastinum is of physiologic size and opacity. The trachea diverges from the thoracic vertebrae, and the carina is located level with T6. A small amount of esophageal air is present in left lateral recumbency.

The lung lobes are well aerated and extend to the thoracic boundaries. Pulmonary vessels are well outlined to the tertiary branches. The bronchial tree is thin walled and tapers towards the periphery.

The cardiac silhouette is tilted cranially. It occupies 65% of the chest height and 2 intercostal spaces. Chamber or outflow tract enlargement is not obvious.

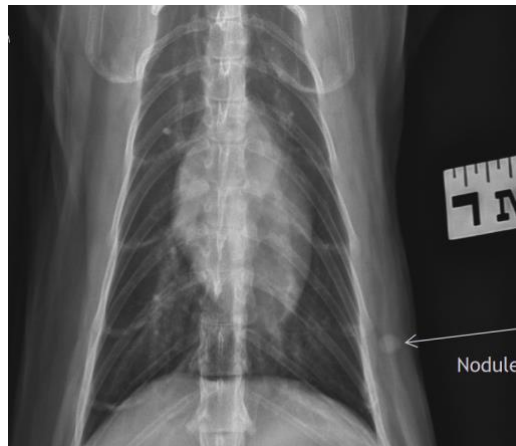
## RADIOGRAPHIC DIAGNOSIS

Incidental finding

- Soft tissue nodule left thoracic wall
- Spondylosis
- Skin nodule

## INTERPRETATION OF THE FINDINGS & FURTHER RECOMMENDATIONS

I can see no mayor pathologies. Cranial tilting of the cardiac silhouette is physiological in older cats. Echocardiography is recommended as an addition to the tests already mentioned.



**The information and recommendations provided are based on the images presented by the referring veterinarian/sonographer. No evaluation can be communicated regarding pathology that was not visible in the image/video clips provided.**

Thank you for this referral. If the clinical or image interpretation does not parallel your findings or if I



**PATIENT**

Mr. Meow Aiken

can be of any further assistance, please contact me.

**Heike Rudolf**, DVM, Dr. med. vet., DipECVDI, DVR  
[info@sonopath.com](mailto:info@sonopath.com)

**SPECIES**

Feline

**BREED**

DSH

**SEX**

Neutered Male

**AGE**

15

**WEIGHT**

13.8

**INTERPRETED BY**

Heike Rudolf, DVM, Dr.  
med. Vet., DipECVDI  
DVR

**IMAGING  
PERFORMED BY**

Dr. Christopher Dewitt

**HOSPITAL NAME**

Williamsburg VC

**REFERRING VET**

Dr. Christopher Dewitt

**INVOICE**

36543

**DATE**

4/10/26