



## PATIENT

Freya Buttery  
Srivarapathy

## SPECIES

Canine

## BREED

American Bully

## SEX

Spayed Female

## AGE

5 Years

## WEIGHT

48.8 kg

## INTERPRETED BY

Heike Rudorf, DVM, Dr.  
med. Vet., DipECVDI  
DVR

## IMAGING PERFORMED BY

MN,AS,NZ

## HOSPITAL NAME

The Collegeway AH

## REFERRING VET

Dr. Mina Nessiem

## INVOICE

36541

## DATE

4/10/26

## PRESENTING CLINICAL SIGNS

History: presented for limping, suspect cruciate injury.

## RADIOGRAPHIC STUDY OF PELVIS AND STIFLES

### Hind legs

The skin surfaces are smooth, and the muscles appear to be symmetrically developed. A small, mineral opacity is located on the left third trochanter.

All bones are well mineralized and have a normal trabecular structure. Cortico-medullary development and differentiation of the long bones are physiological.

Pelvis: the center of both femoral heads is superimposed onto the respective dorsal acetabular edge. Both cranial acetabular edges are slightly sclerotic and laterally thickened. New bone (NB) surrounds the femoral head and fills the dorsal aspect of the femoral neck. A Morgan line is visible bilaterally.

Stifles: the joint presents with smooth, subchondral bone surfaces. The center of the femoral condyles is located caudal to the intercondylar eminence of the tibia. The cranial fat pad is markedly reduced, and the caudal fascial plains are obscured by a soft tissue opacity in the joint. A small amount of NB formation is present on both poles of the patella the proximal femoral ridges, condyles, fabellae and the tibial plateau.

## RADIOGRAPHIC DIAGNOSIS

Bilateral stifles

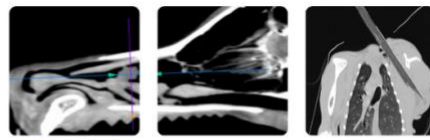
- Cruciate ligament rupture

Incidental finding

- Bilateral HD with arthrosis, moderate
- Insertion desmopathy left M. iliopsoas

## INTERPRETATION OF THE FINDINGS & FURTHER RECOMMENDATIONS

The imaging changes are, as suspected, compatible with bilateral cruciate disease. Surgery is recommended.



## PATIENT

Freya Buttery  
Srivarapathy

## SPECIES

Canine

## BREED

American Bully

## SEX

Spayed Female

## AGE

5 Years

## WEIGHT

48.8 kg

## INTERPRETED BY

Heike Rudorf, DVM, Dr.  
med. Vet., DipECVDI  
DVR

## IMAGING PERFORMED BY

MN,AS,NZ

## HOSPITAL NAME

The Collegeway AH

## REFERRING VET

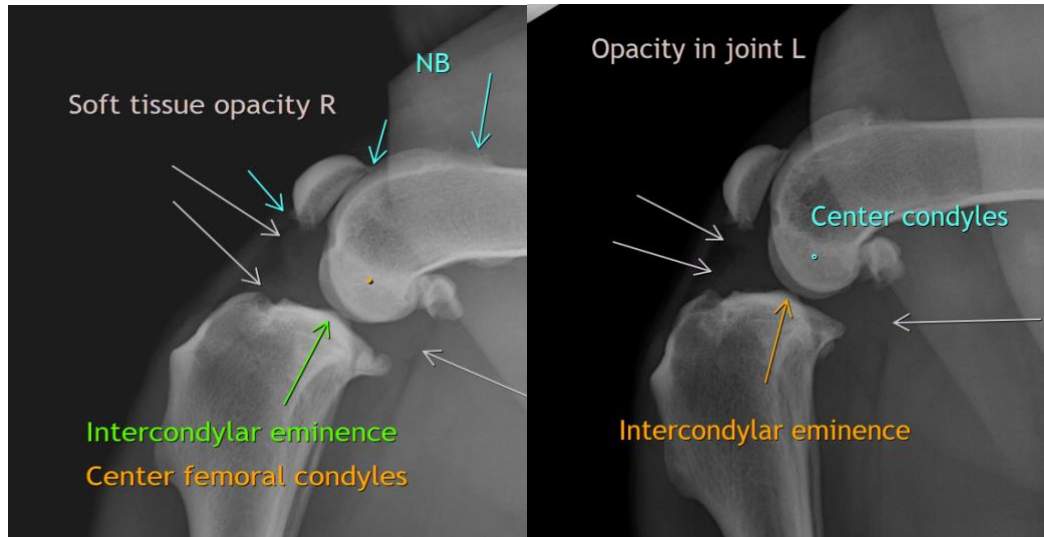
Dr. Mina Nessiem

## INVOICE

36541

## DATE

4/10/26



The information and recommendations provided are based on the images presented by the referring veterinarian/sonographer. No evaluation can be communicated regarding pathology that was not visible in the image/video clips provided.

Thank you for this referral. If the clinical or image interpretation does not parallel your findings or if I can be of any further assistance, please contact me.

**Heike Rudorf**, DVM, Dr. med. vet., DipECVDI, DVR  
[info@sonopath.com](mailto:info@sonopath.com)