



PATIENT PRESENTING CLINICAL SIGNS

Astro Hart P came in for a cough that's been going on for some time. O mentioned that P goes to the groomer. Other pet in the house is acting fine. No time of day that it is worse. O concerned because she has had other dogs with blasto and hemangiosarc issues and wants to be proactive.
SPECIES Abnormal PE/Chem/CBC/UA Results: Apparently healthy - no cough during exam.

Canine **RADIOGRAPH OF THE THORAX**

Thorax: RLR, LLR, VD
 Neck: R and LLR

BREED RADIOGRAPHIC FINDINGS

Goldendoodle The body condition score is 7/9 with smooth alternating layers of fat and soft tissue opacity.

SEX The bony structures appear physiological.

MC The degree of pulmonary expansion is fair, and the caudal heart border is in close contact with the cupola of the diaphragm in all three views. The lungs are in contact with the thoracic boundaries and the tips are pointed. The lobar vessels are clearly visible to the tertiary branches. The bronchial tree is thin walled and tapers uniformly towards the periphery.

AGE The cranial mediastinum is of physiological size and opacity. The trachea diverges from the thoracic vertebrae and the carina is located at T5. A small amount of air is present in the esophagus.

5 Years The cardiac silhouette occupies 75% of the chest height and 3 intercostal spaces. No chamber or outflow tract enlargement is evident.

INTERPRETED BY

Heike Rudolf, DVM,
 Dr. med. Vet.,
 DipECVDDI DVR

HOSPITAL NAME RADIOGRAPHIC DIAGNOSIS

Bayshore Veterinary Hospital • Physiological thorax

INTERPRETATION OF THE FINDINGS & FURTHER RECOMMENDATIONS

REFERRING VET I can see no changes that would explain the clinical signs described by the owner. Even though the close contact between heart and diaphragm makes the assessment of the accessory lobe difficult, on the VD view the borders of both are clearly demarcated, suggesting a physiological aeration. However, bronchitis (e.g. allergic origin) can be present without radiographic evidence and thus bronchoscopy with broncho-alveolar lavage should be considered if clinical signs worsen. In case the clinical signs are only present at home, care should be taken to identify if any changes to the household have been made e.g. buying a new carpet or rug, new washing powder or other cleaning agents.

Lara Stephens-Brown

INVOICE

51294

TECHNICAL COMMENTS

DATE Only jpg images were submitted. The transformation from DICOM to jpg reduces the image quality and only allows limited manipulation of the image. More subtle lesions can thus easily be missed. For the best possible imaging reports, I suggest submitting DICOM images in the future.

4-1-22



PATIENT

Astro Hart

SPECIES

Canine

BREED

Goldendoodle

SEX

MC

AGE

5 Years

INTERPRETED BY

Heike Rudolf, DVM,
Dr. med. Vet.,
DipECVDDI DVR

HOSPITAL NAME

Bayshore Veterinary
Hospital

REFERRING VET

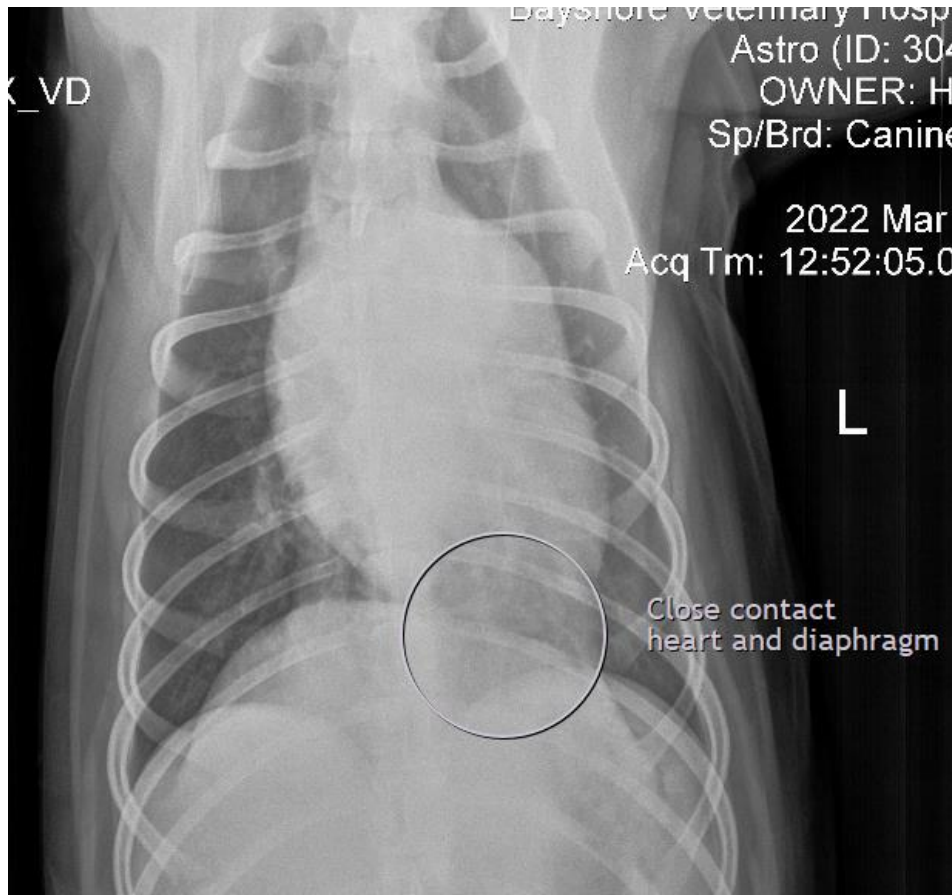
Lara Stephens-Brown

INVOICE

51294

DATE

4-1-22



The information and recommendations provided are based on the images presented by the referring veterinarian/sonographer. No evaluation can be communicated regarding pathology that was not visible in the image/video clips provided.

Thank you for this referral. If the clinical or image interpretation does not parallel your findings or if I can be of any further assistance please contact me.

Heike Rudolf, DVM, Dr. med. vet., DipECVDDI, DVR
Dr.H.Rudorf@gmail.com