

## PATIENT

Tony Vanore

## SPECIES

Canine

## BREED

Pitbull X

## SEX

Neutered Male

## AGE

4 Years

## WEIGHT

40.5

## INTERPRETED BY

Heike Rudorf, DVM, Dr.  
med. Vet., DipECVDI  
DVR

## IMAGING PERFORMED BY

BF

## HOSPITAL NAME

Green Dog Dental &  
Wellness

## REFERRING VET

Dr. Geist

## INVOICE

36141

## DATE

3/7/26

## PRESENTING CLINICAL SIGNS

History: Left stifle area palpably thickened, hesitant to bear full weight on left hind limb following manipulation. \*under sedation mild drawer sign left stifle

## RADIOGRAPHIC STUDY OF PELVIS AND STIFLES

### Hind legs

The muscle mass surrounding the left femur is reduced.

All bones are well mineralized, have a normal trabecular structure and smooth, continuous surfaces. Cortico-medullary development and differentiation of the long bones are physiological.

Pelvis: the center of the right femoral head is located medial to the dorsal acetabular edge; on the left it is superimposed onto the dorsal acetabular edge. Both coxo-femoral joints present smooth osseous margins and congruent joint spaces.

Stifle R: the joint presents with smooth, subchondral bone surfaces and the center of the femoral condyles is in line with the intercondylar eminence of the tibia. The cranial fat pad is slightly reduced and the cranial meniscus obscured. The caudal fascial plains are proximally very slightly compressed. A smooth bone spur is located on the caudal femoral cortex level with the origin of the gastrocnemius muscle and larger than on the left.

Stifle L: the joint presents with smooth, subchondral bone surfaces. The center of the femoral condyles is located in line with the intercondylar eminence of the tibia. The cranial fat pad is reduced, and the caudal fascial plains are partially obscured and caudally displaced by a soft tissue opacity in the joint. A small amount of new bone (NB) formation is present on the distal pole of the patella, the proximal femoral ridges, and fabellae as well as the tibial insertion of the cranial cruciate ligament and lateral tibial plateau.

## RADIOGRAPHIC DIAGNOSIS

### L stifle

- Effusion/Fibrosis
- Arthrosis, mild
- Muscle atrophy

### R stifle

- Very mild effusion
- Bone spur caudal cortex, mild

## INTERPRETATION OF THE FINDINGS & FURTHER RECOMMENDATIONS

The changes on the left are compatible with cruciate ligament damage and may represent a partial or complete tear. The radiographic muscle atrophy should be clinical confirmed with a tape measure because it suggests a long-standing problem. Depending on the duration of the lameness, the atrophy may or may not be solely due to the cruciate disease. In the latter case, further examinations, e.g., spine, lumbar plexus nerves, may be necessary. The changes on the right are mild and could be due to overuse or indicate the beginning of cruciate disease or meniscal damage. The spur on the caudal femur can be innocuous or may be associated with gastrocnemius myositis. However, as there are no clinical signs on the right, disease is unlikely.



## PATIENT

Tony Vanore

## SPECIES

Canine

## BREED

Pitbull X

## SEX

Neutered Male

## AGE

4 Years

## WEIGHT

40.5

## INTERPRETED BY

Heike Rudolf, DVM, Dr.  
med. Vet., DipECVDI  
DVR

## IMAGING PERFORMED BY

BF

## HOSPITAL NAME

Green Dog Dental &  
Wellness

## REFERRING VET

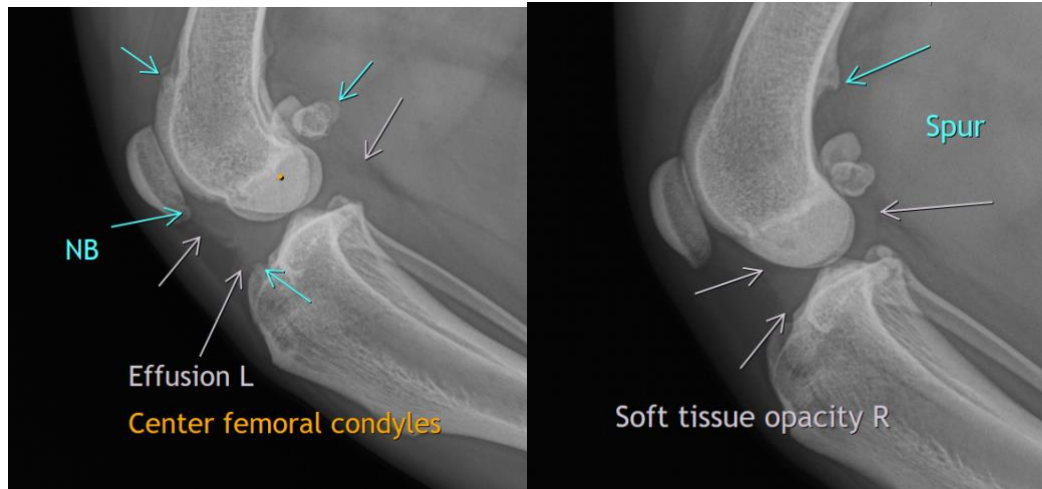
Dr. Geist

## INVOICE

36141

## DATE

3/7/26



The information and recommendations provided are based on the images presented by the referring veterinarian/sonographer. No evaluation can be communicated regarding pathology that was not visible in the image/video clips provided.

Thank you for this referral. If the clinical or image interpretation does not parallel your findings or if I can be of any further assistance, please contact me.

**Heike Rudolf, DVM, Dr. med. vet., DipECVDI, DVR**  
[info@sonopath.com](mailto:info@sonopath.com)