

## PATIENT

Jager Budd

## SPECIES

Canine

## BREED

German Shepherd

## SEX

Intact Male

## AGE

12 Years

## WEIGHT

90 Pounds

## INTERPRETED BY

Heike Rudorf, DVM, Dr.  
med. Vet., DipECVDI  
DVR

## IMAGING PERFORMED BY

Allison, LVT and  
Mandy, LVT

## HOSPITAL NAME

Gentle Doctor AH

## REFERRING VET

Dr. Hayes

## INVOICE

36130

## DATE

3/5/26

## PRESENTING CLINICAL SIGNS

Patient presented 2 weeks ago for right forelimb lameness. Sent home with Carprofen.

Patient presented again on 3/5 with worsening lameness localized to the right shoulder.

Abnormal PE/Chem/CBC/UA Results: Right shoulder pain elicited during extension/flexion. Concerns for osteolytic lesion in the proximal aspect of right humerus.

## RADIOGRAPHIC STUDY OF RIGHT SHOULDER

The muscle mass appears to be reduced.

A focal loss of trabecular structure results in lysis in the region of the greater tubercle. Up to 5cm distal to it, the medullary cavity appears sclerotic which is associated with irregular periosteal reactions. The cranial reaction extends approx. 3cm further distally along the femoral crest. Proximally the periosteal reaction is fluffy and the cortex thin.

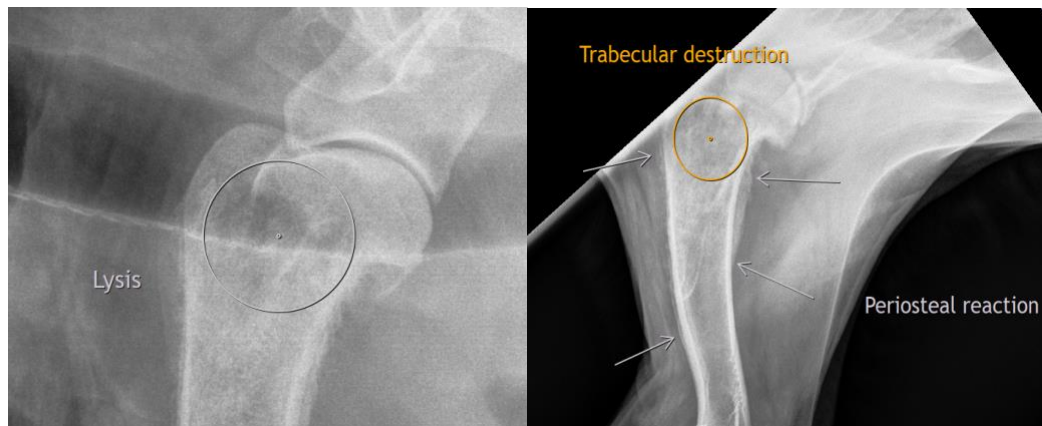
Osteophytes are present on both caudal humeral heads.

## RADIOGRAPHIC DIAGNOSIS

- Bone tumor proximal R humerus
- Shoulder arthrosis, bilateral

## INTERPRETATION OF THE FINDINGS & FURTHER RECOMMENDATIONS

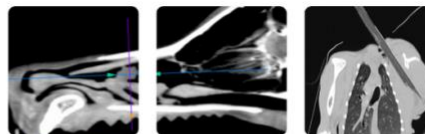
The changes are compatible with a primary bone tumor, likely a mixed type osteosarcoma. Due to the lysis a fracture is possible in the future. Considering the shoulder arthrosis on the left, amputation is unlikely to help the dog. Palliative radiotherapy can be tried. A thoracic imaging modality should be used to look for metastases.



**The information and recommendations provided are based on the images presented by the referring veterinarian/sonographer. No evaluation can be communicated regarding pathology that was not visible in the image/video clips provided.**

Thank you for this referral. If the clinical or image interpretation does not parallel your findings or if I can be of any further assistance, please contact me.

**Heike Rudorf, DVM, Dr. med. vet., DipECVDI, DVR**



**PATIENT**

[info@sonopath.com](mailto:info@sonopath.com)

Jager Budd

**SPECIES**

Canine

**BREED**

German Shepherd

**SEX**

Intact Male

**AGE**

12 Years

**WEIGHT**

90 Pounds

**INTERPRETED BY**

Heike Rudorf, DVM, Dr.  
med. Vet., DipECVDI  
DVR

**IMAGING  
PERFORMED BY**

Allison, LVT and  
Mandy, LVT

**HOSPITAL NAME**

Gentle Doctor AH

**REFERRING VET**

Dr. Hayes

**INVOICE**

36130

**DATE**

3/5/26