



<b>PATIENT</b>	<b>PRESENTING CLINICAL SIGNS</b>
Pop Tart Lindquist	Dog presented lame right hind leg with several months duration. Dog is full weight bearing but limp is subtle but noticeable. No pain on palpation or manipulation of leg. No cranial drawer or tibial thrust under sedation. Radiographs taken for evaluation
<b>SPECIES</b>	<b>RADIOGRAPH OF THE STIFLES</b>
K9	1x VD pelvis including stifles, R and L lat. stifle, cranio-caudal tibiae, including stifles and paws
<b>BREED</b>	<b>RADIOGRAPHIC FINDINGS</b>
Bull Terrier	Both stifle joints have smooth subchondral bone surfaces, and the centre of the femoral condyles is in line with the intercondylar eminence. The cranial fat pad has a physiological size, and the caudal fascial plains are in a physiological position. New bone formation is not evident. Both patellae are superimposed onto the ipsilateral medial condyle.
<b>SEX</b>	
F	The right medial tibiotarsal joint space appears to be larger than the left and the medial ridge appears flattened. Bilateral medial soft tissue swelling appears to be present.
<b>AGE</b>	<b>RADIOGRAPHIC DIAGNOSIS</b>
1 Year, 2 Months	<ul style="list-style-type: none"><li>• Possible patella subluxation</li><li>• Possible tarsal OCD</li></ul>
<b>INTERPRETED BY</b>	<b>INTERPRETATION OF THE FINDINGS &amp; FURTHER RECOMMENDATIONS</b>
Heike Rudolf, DVM, Dr. med. Vet., DipECVDI DVR	The position of the patellae could be related to the limited inward rotation of the joint but may be a sign of low-grade patella luxation. Palpation will show if the patella can be displaced manually.
<b>HOSPITAL NAME</b>	The changes may be located in the hock joints and if clinical examination is suggestive of a disease process, CT is recommended to assess the joint spaces accurately and help identify the OCD fragment.
Blairstown Animal Hospital	<b>TECHNICAL COMMENTS</b>
<b>REFERRING VET</b>	Both stifles joints are oblique on the cranio-caudal views. No side marker on VD pelvis.
Dr. Leal	
<b>INVOICE</b>	
50719	
<b>DATE</b>	
3-4-22	



**PATIENT**

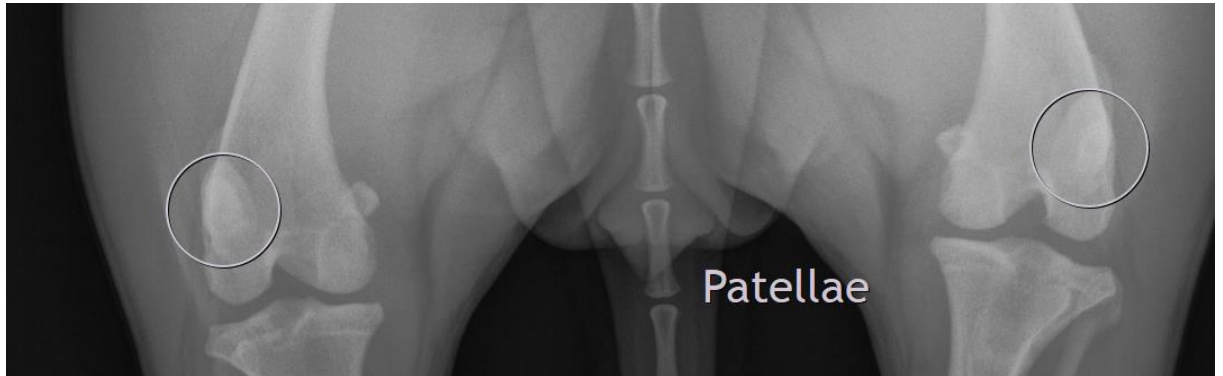
Pop Tart Lindquist

**SPECIES**

K9

**BREED**

Bull Terrier



**SEX**

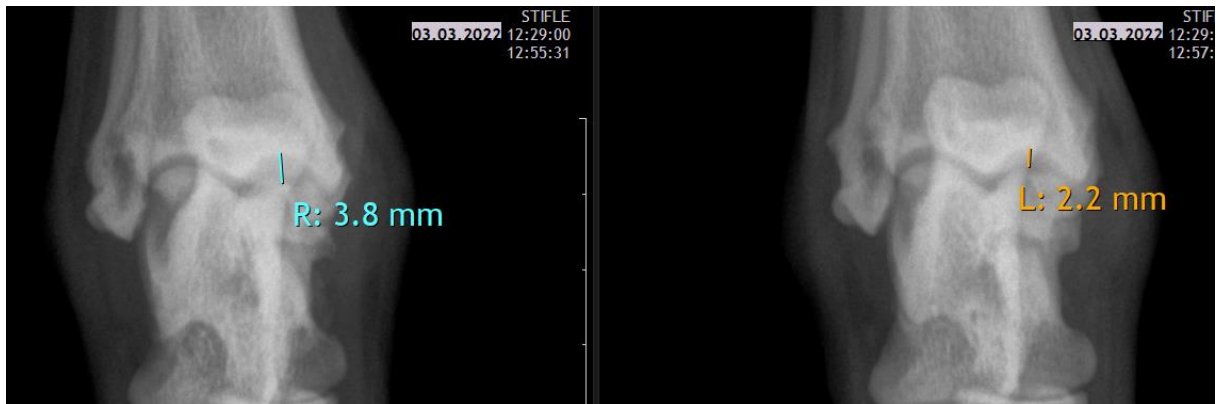
F

**AGE**

1 Year, 2 Months

**INTERPRETED BY**

Heike Rudorf, DVM,  
Dr. med. Vet.,  
DipECVDDI DVR



**HOSPITAL NAME**

Blairstown Animal  
Hospital

**REFERRING VET**

Dr. Leal

The information and recommendations provided are based on the images presented by the referring veterinarian/sonographer. No evaluation can be communicated regarding pathology that was not visible in the image/video clips provided.

Thank you for this referral. If the clinical or image interpretation does not parallel your findings or if I can be of any further assistance please contact me.

**Heike Rudorf, DVM, Dr. med. vet., DipECVDDI, DVR**  
Dr.H.Rudorf@gmail.com

**INVOICE**

50719

**DATE**

3-4-22