



PATIENT PRESENTING CLINICAL SIGNS

Ozzie Slaibe
SPECIES Canine
 History: MEDIASTINAL LYMPHOMA PROGRESSIVE DESPITE CHEMOTHERAPY RECENTLY COUGHING MORE History: 12 y/o MN mini poodle presented for annual vaccines. No current concerns, P doing well per O. Owner reduced pred from 5mg 1 tab BID to 1 tab am, 1/2 pm and has continued to do well. C/S/V/D: wnl E/D/U/D: wnl Diet: Cooked turkey breast w/ stella and chewy FAS Score: 0 Current Medications (dose and frequency): Prednisone 5mg 1 tab PO (am) 1/2 tab PO (pm)/ Hycodan 5mg 1/2 q4h/ Dasuquin chews Heartworm Prevention / Flea Prevention: Triflexus Known Allergies and Medical Conditions: collapsing trachea/arthritis Vaccine Reactor: Yes No Unknown **Scan for Microchip! AVID*044*083*043

BREED Min Poodle
 Abnormal PE/Chem/CBC/UA Results: Vital Signs Weight: 14.7 lbs Temp: HR: coughing RR: coughing MM/CRT: Physical Examination Key -- (N= Normal, A= Abnormal) Hydration: N Mentation: N EENT: N Oral Cavity: N Lymph Nodes: N Skin: N CV/Respiratory: Mildly increased BV sounds Abd/GI: Hepatomegaly. Rectal - AG's full, hard to express, thick material Uro/Perineum: N Musculoskeletal: DJD elbows Neurological: N Diagnostic Testing Needed: Declined Diagnostics:

SEX Neutered Male
 Findings: HW4dx: Negative HW+ Ehrlichia+ Anaplasmosis+ Lyme+ Declined/Not Performed Fecal: Assessment: Mediastinal LSA Treatments: Continue with Pred, Hycodan, alternative therapy at Healing Paws Owner may try to reduce pred to 5mg SID in a couple weeks. Cough has improved since d/c chemo and going to Healing Paws. Rec no vaccines given LSA, only due for DP today RV: Right Rear SQ Not Given/Not Due DA2PP: Front Right SQ Left Rear SQ Titer Performed, results pending Bordetella: Orally Injectable SQ Additional Vaccines Given: Lepto4 Influenza H3N2

AGE 12 Years 11 Months
 Preventative: Adv-Multi Triflexus Interceptor Plus Credelio Simparica Trio ProHeart6 Other: Prescriptions to Dispense: Dietary (food) Recommendations: Additional Comments: Doing very well, looks brighter and happier than has in awhile but we all understand that the LSA will eventually start to worsen his cough and negatively affect his QOL.

INTERPRETED BY RADIOGRAPHIC STUDY OF THE THORAX

Heike Rudolf, DVM, Dr. med. Vet., DipECVDI DVR
 The body condition score is 7/9 with smooth alternating layers of fat and soft tissue opacity. Mild ventral spondylosis is visible at the thoraco-lumbar junction.

HOSPITAL NAME DPC Veterinary Hospital
 A large, soft tissue mass is present in the cranial thorax, displacing the trachea dorsally and to the right. On the lateral views the carina is compressed. The mass also displaces both cranial lobes caudally. On the DV view the region of the caudal vena cava is obscured by a soft tissue opacity and the right main stem bronchus is not visible. The centrally located left lungs also show an increase in opacity which appears to affect the cranio-dorsal lobe on one lateral view. On one lateral recumbent view lobulated soft tissue masses appear to be present in the ventral thorax.

REFERRING VET The cardiac silhouette is difficult to assess.

Dr. Feldt RADIOGRAPHIC DIAGNOSIS

- Cranial mediastinal mass
- Suspicion of pulmonary involvement
- Enlargement of bronchial and perhaps sternal lymph node
- Compression of carina
- Poorly ventilated R main stem bronchus

INVOICE

21896

INTERPRETATION OF THE FINDINGS & FURTHER RECOMMENDATIONS

DATE

3/31/23



PATIENT

Ozzie Slaibe

The changes are consistent with the known cranial mediastinal lymphoma. Currently lymph nodes appear to be affected as well. The carina is severely compressed and the right main bronchus appears to be compromised. This could result in acute respiratory compromise if the compression progresses.

SPECIES

Canine

BREED

Min Poodle

SEX

Neutered Male

AGE

12 Years 11 Months

INTERPRETED BY

Heike Rudolf, DVM,
Dr. med. Vet.,
DipECVDI DVR

HOSPITAL NAME

DPC Veterinary
Hospital

REFERRING VET

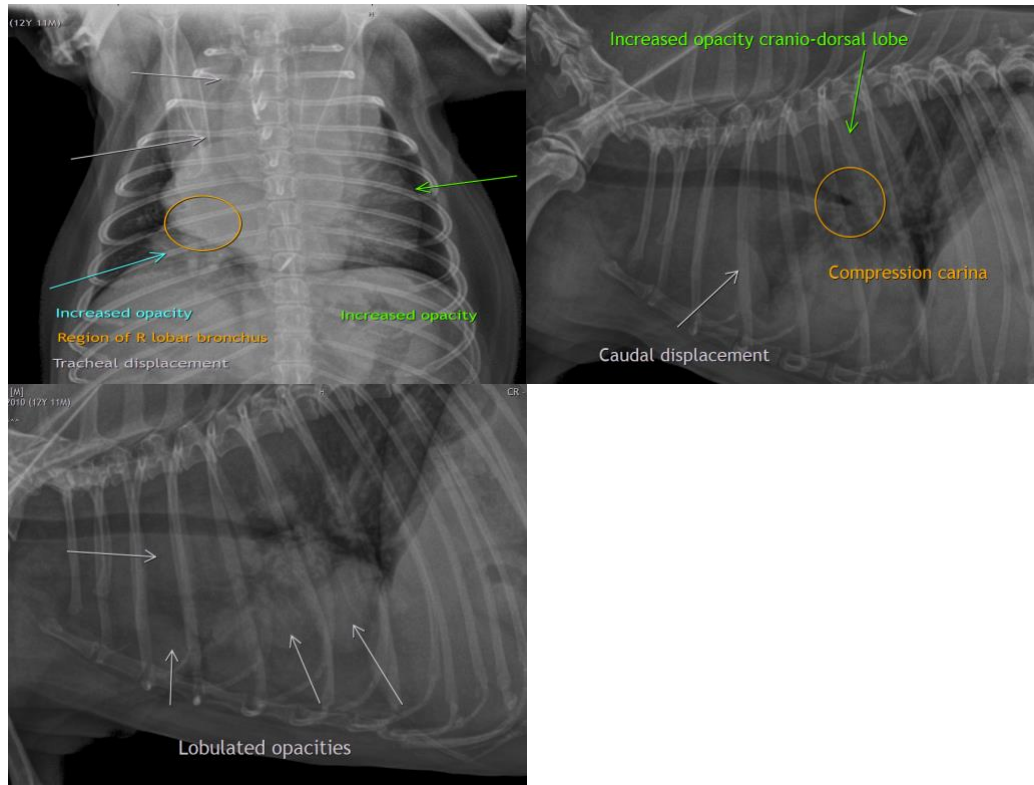
Dr. Feldt

INVOICE

21896

DATE

3/31/23



The information and recommendations provided are based on the images presented by the referring veterinarian/sonographer. No evaluation can be communicated regarding pathology that was not visible in the image/video clips provided.

Thank you for this referral. If the clinical or image interpretation does not parallel your findings or if I can be of any further assistance please contact me.

Heike Rudolf, DVM, Dr. med. vet., DipECVDI, DVR
dr.h.rudorf@gmail.com



PATIENT

Ozzie Slaibe

SPECIES

Canine

BREED

Min Poodle

SEX

Neutered Male

AGE

12 Years 11 Months

INTERPRETED BY

Heike Rudolf, DVM,
Dr. med. Vet.,
DipECVDI DVR

HOSPITAL NAME

DPC Veterinary
Hospital

REFERRING VET

Dr. Feldt

INVOICE

21896

DATE

3/31/23