



PATIENT PRESENTING CLINICAL SIGNS

Lulu Espiritu History: Painful when touching the back. sometimes left back limb knuckling started 3 days ago. No falling, slipping or abnormal jumping.

SPECIES

Canine

Abnormal PE/Chem/CBC/UA Results: Pain around the lumbosacral area. Normal proprioception of all 4 limbs. BW: Mild increase in glucose, ALT and marked increase in ALKP. Erythron and Leukon are NSF.

RADIOGRAPHIC STUDY OF THE T- AND L-SPINE

BREED

Dachshund

The surrounding muscles and fat layers appear physiological. Number and shape of the vertebrae are physiological. No structural alterations are evident along the thoracic and lumbar spine. No signs of aggressive osteolysis have been identified.

SEX

Spayed Female

The T12/13-disc spaces appear smaller than the adjacent ones and the intervertebral foramen at the LS junction is increased in opacity.

The ventral liver lobe appears blunted, and the gastric axis is slightly caudally rotated.

AGE

9 Years

RADIOGRAPHIC DIAGNOSIS

- Possible disc disease T12/13 and L7/S1
- Hepatomegaly

INTERPRETED BY

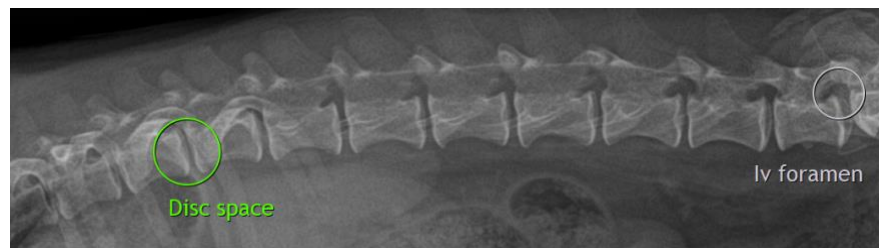
Heike Rudorf, DVM,
Dr. med. Vet.,
DipECVDI DVR

INTERPRETATION OF THE FINDINGS & FURTHER RECOMMENDATIONS

Accurate positioning of the spine is difficult, even under G.A., and cord compression can only be identified with myelography or in cross sectional imaging. Depending on the severity of the clinical signs, CT or MRI will be necessary in case an extruded disc needs to be removed. Additional tests should be performed to rule out Cushing's disease (e.g. ultrasound, ACTH stimulation test).

HOSPITAL NAME

Truscott AH



REFERRING VET

Dr, Medhat Meawad

INVOICE

21895

The information and recommendations provided are based on the images presented by the referring veterinarian/sonographer. No evaluation can be communicated regarding pathology that was not visible in the image/video clips provided.

Thank you for this referral. If the clinical or image interpretation does not parallel your findings or if I can be of any further assistance please contact me.

DATE

3/31/23



PATIENT **Heike Rudolf**, DVM, Dr. med. vet., DipECVDI, DVR
dr.h.rudorf@gmail.com

Lulu Espiritu

SPECIES

Canine

BREED

Dachshund

SEX

Spayed Female

AGE

9 Years

INTERPRETED BY

Heike Rudolf, DVM,
Dr. med. Vet.,
DipECVDI DVR

HOSPITAL NAME

Truscott AH

REFERRING VET

Dr, Medhat Meawad

INVOICE

21895

DATE

3/31/23