



PATIENT

Noo Puleo

SPECIES

Feline

BREED

DSH

SEX

Spayed Female

AGE

7.5 Years

WEIGHT

13 pounds

INTERPRETED BY

Heike Rudolf, DVM, Dr.
med. Vet., DipECVDF
DVR

IMAGING PERFORMED BY

Jen Amidon

HOSPITAL NAME

The Pet Hospital of
Stratford

REFERRING VET

Dr. David

INVOICE

14714

DATE

03/27/26

PRESENTING CLINICAL SIGNS

Pt has had a hacking cough for a few weeks. Otherwise doing well.

RADIOGRAPHIC STUDY OF THE THORAX

R/L lateral and VD are provided, totaling three radiographs for interpretation.

27.03.2026

RADIOGRAPHIC FINDINGS

The body condition score is 8/9 with smooth, alternating layers of fat and soft tissue opacity.

The bony structures appear physiological.

The cranial mediastinum is of physiologic size and opacity. The trachea diverges from the thoracic vertebrae, and the carina is located level with T5/6.

The degree of pulmonary expansion is only fair, and the cranio-ventral lobes are dorsally displaced by fat. Secondary and tertiary pulmonary branches are poorly outlined. The bronchial tree is highlighted in the periphery.

The cardiac silhouette occupies 75% of the chest height and 2 intercostal spaces. Chamber or outflow tract enlargement is not obvious.

RADIOGRAPHIC DIAGNOSIS

- Interstitial pattern
- Reduced pulmonary expansion
- Obesity

INTERPRETATION OF THE FINDINGS & FURTHER RECOMMENDATIONS

An interstitial lung pattern is a non-specific finding and accentuated by the only fair expansion of the lung field and obesity. Possible differential diagnoses for a true infiltrate include:

- Infection (bacterial, fungal parasitic e.g., aelurostrongylus)
- Inflammation (allergic pneumonitis, eosinophilic bronchopneumopathy,)
- Early idiopathic fibrosis
- Edema
- Diffuse hemorrhage
- Tumor (e.g., lymphoma)

Fecal samples should be obtained to rule out parasites. Tracheo-bronchoscopy with broncho-alveolar lavage is recommended; samples should be submitted for bacteriological and cytological examination. Prior to intubation tonsil and laryngeal movement should be assessed.

Obesity is known to worsen clinical signs of cough and impair lung function; weight control is strongly recommended.



PATIENT

Noo Puleo

SPECIES

Feline

BREED

DSH

SEX

Spayed Female

AGE

7.5 Years

WEIGHT

13 pounds

INTERPRETED BY

Heike Rudolf, DVM, Dr.
med. Vet., DipECVDI
DVR

IMAGING PERFORMED BY

Jen Amidon

HOSPITAL NAME

The Pet Hospital of
Stratford

REFERRING VET

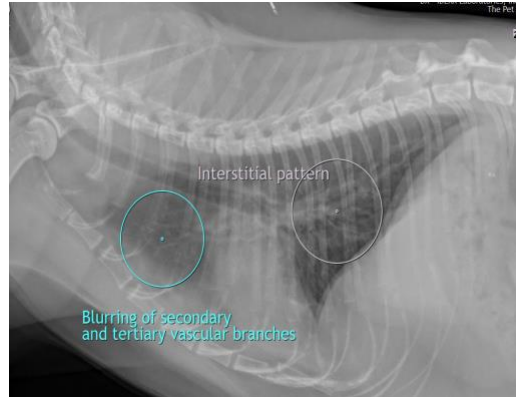
Dr. David

INVOICE

14714

DATE

03/27/26



The information and recommendations provided are based on the images presented by the referring veterinarian/sonographer. No evaluation can be communicated regarding pathology that was not visible in the image/video clips provided.

Thank you for this referral. If the clinical or image interpretation does not parallel your findings or if I can be of any further assistance, please contact me.

Heike Rudolf, DVM, Dr. med. vet., DipECVDI, DVR
info@sonopath.com