



PATIENT

Luna Saracino

SPECIES

Canine

BREED

Mixed

SEX

Spayed Female

AGE

8

WEIGHT

12

INTERPRETED BY

Heike Rudolf, DVM, Dr.
med. Vet., DipECVDD
DVR

IMAGING PERFORMED BY

Dr. Kristin Potenzzone
DVM

HOSPITAL NAME

Legacy Animal Hospital

REFERRING VET

Dr. Kristin Potenzzone
DVM

INVOICE

14715

DATE

03/27/26

PRESENTING CLINICAL SIGNS

Acute onset RH lameness, no injury noted by owner

RADIOGRAPHIC STUDY OF THE STIFLES

R/L lateral and VD, totaling 3 radiographs provided for interpretation.

Undated, non-DICOM images

RADIOGRAPHIC FINDINGS

Hind Legs

The skin surfaces are smooth, and the muscles appear to be symmetrically developed.

All bones are well mineralized, have a normal trabecular structure and smooth, continuous surfaces. Cortico-medullary development and differentiation of the long bones are physiological.

Stifle L

The joint presents with smooth osseous margins. The cranial fat pad has a physiological size; the caudal fascial plains are not clearly visible. New bone formation is not evident, and the patella is located centrally in its groove.

Stifle R

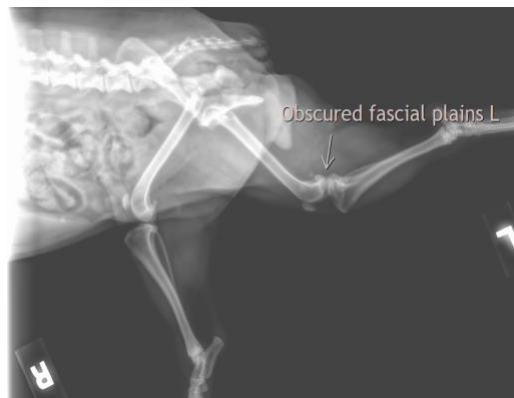
The joint is superimposed onto the ventral abdominal wall. It presents with smooth osseous margins. The cranial fat pad appears to have a physiological size; the caudal fascial plains are in a physiological position. New bone formation is not evident, and the patella is superimposed onto the lateral condyle.

RADIOGRAPHIC DIAGNOSIS

- Physiological study

INTERPRETATION OF THE FINDINGS & FURTHER RECOMMENDATIONS

The fascial plains are obscured on the left, where the dog is not lame. It likely represents an artefact. In the absence of convincing radiographic signs, I suggest conservative treatment and reassessment in 7-10 days. Should changes be identify during the repeat orthopedic examination, radiographs centered on the area of interest are recommended. Alternatively, a contrast CT examination can be performed to rule out myositis and tendinitis.





PATIENT

Luna Saracino

SPECIES

Canine

BREED

Mixed

SEX

Spayed Female

AGE

8

WEIGHT

12

INTERPRETED BY

Heike Rudolf, DVM, Dr.
med. Vet., DipECVDI
DVR

IMAGING PERFORMED BY

Dr. Kristin Potenzzone
DVM

HOSPITAL NAME

Legacy Animal Hospital

REFERRING VET

Dr. Kristin Potenzzone
DVM

INVOICE

14715

DATE

03/27/26

The information and recommendations provided are based on the images presented by the referring veterinarian/sonographer. No evaluation can be communicated regarding pathology that was not visible in the image/video clips provided.

Thank you for this referral. If the clinical or image interpretation does not parallel your findings or if I can be of any further assistance, please contact me.

Heike Rudolf, DVM, Dr. med. vet., DipECVDI, DVR
info@sonopath.com