



PATIENT

Lola Hunt

SPECIES

Canine

BREED

Boxer Mix

SEX

Spayed Female

AGE

5 Years 9 Months

WEIGHT

64.4 Pounds

INTERPRETED BY

Heike Rudolf, DVM, Dr.
med. Vet., DipECVDI
DVR

IMAGING PERFORMED BY

GC/JA

HOSPITAL NAME

The Pet Hospital of
Stratford

REFERRING VET

Dr. Claudia Giuliani,
DVM

INVOICE

36313

DATE

3/20/26

PRESENTING CLINICAL SIGNS

History: Lola presents for limping on RR leg. Mom says that she let her outside this morning and when she came back, she was limping. On PE, distal phalange of D4 RH was movable medially.

RADIOGRAPHIC STUDY OF THE RIGHT HIND PAW

Digit 4

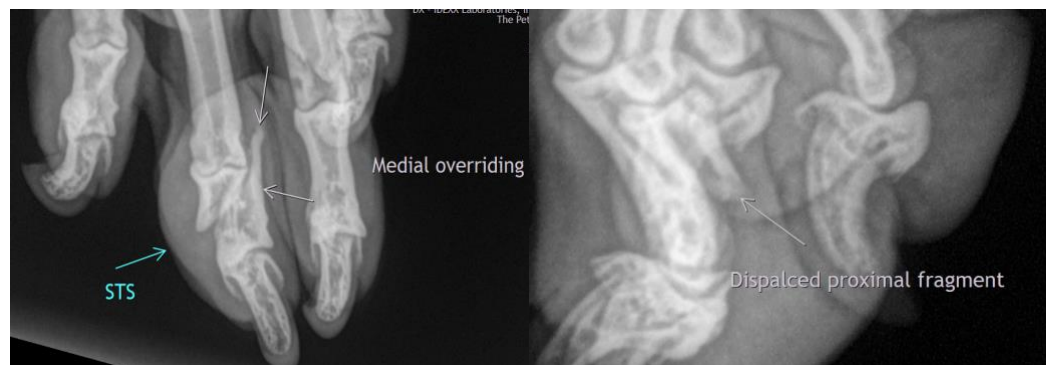
A transverse fracture is present in P2 with medial overriding of the distal fragment. On the lateral view the proximal fragment is caudally displaced. The fracture ends are pointed. A mild degree of soft tissue swelling (STS) surrounds the bone and adjacent joints.

RADIOGRAPHIC DIAGNOSIS

- Fracture digit 4 P2

INTERPRETATION OF THE FINDINGS & FURTHER RECOMMENDATIONS

Clinical and radiographic findings support each other in the diagnosis of a fracture. Repositioning of the overriding fragment is recommended.



The information and recommendations provided are based on the images presented by the referring veterinarian/sonographer. No evaluation can be communicated regarding pathology that was not visible in the image/video clips provided.

Thank you for this referral. If the clinical or image interpretation does not parallel your findings or if I can be of any further assistance, please contact me.

Heike Rudolf, DVM, Dr. med. vet., DipECVDI, DVR
info@sonopath.com