



PATIENT

Briggs Scott

SPECIES

Canine

BREED

Border Collie

SEX

Neutered Male

AGE

10 Years

WEIGHT

52.4 pounds

INTERPRETED BY

Heike Rudolf, DVM, Dr.
med. Vet., DipECVDI
DVR

IMAGING PERFORMED BY

Kevin & Katy

HOSPITAL NAME

Elizabeth Animal
Hospital

REFERRING VET

Dr. Kim Allyn DVM

INVOICE

14518

DATE

03/20/25

PRESENTING CLINICAL SIGNS

During previous (2/27/2026) examination, it was noted that Briggs has decreased muscle mass, particularly on the left front leg, and crepitus in both elbows, suggesting possible arthritis and elbow dysplasia. He is currently on Rimadyl for forelimb lameness due to a previous injury. He has further evacuation of his lameness and orthopedic issues after he his response to gabapentin is determined. They have been discussing his lameness with an orthopedist. Doctor did recommend radiographs of both elbows as they suspect a bilateral condition and arthritis.

PE: Decreased muscle mass in the rear; muscle wasting primarily on the left front; crepitus in both elbows; poor range of motion in both elbows; bowlegged stance; possible elbow dysplasia bilaterally.

RADIOGRAPHIC STUDY OF PELVIS AND ELBOWS

R/L lateral and VD, totaling 6 radiographs provided for interpretation.

20.03.2026

RADIOGRAPHIC FINDINGS

The bones are well mineralized, have a normal trabecular structure and smooth, continuous surfaces. Cortico-medullary development and differentiation of the long bones are physiological.

Elbow L (cranio-caudal only): the subchondral bone of the medial condyle is smooth. A small amount of smooth new bone (NB) is present along the medial aspect of the ulna. Lipping of the medial coronoid process (MCP) due to smooth new bone formation is present. A bone spur is located on the medial epicondyle.

Shoulder L: the muscle mass along the humerus is decreased. NB is present on lateral aspect of the joint and acromion. An approx. 1cm roundish calcium deposit is located on the medial aspect of the proximal humerus.

Elbow R: a large amount of new bone surrounds the elbow joint and makes full extension impossible. The anconeal process shows an irregular, faint lucent line. The joint spaces are narrow. The surrounding soft tissues are increased and hardly any fat is evident to outline the fascial plains. Small mineral deposits are present in the soft tissues close to the ebony surfaces.

Pelvis: osseous and surrounding soft tissue structures of the pelvis are within normal limits. The center of both femoral heads is located medial to the respective dorsal acetabular edge. Both coxo-femoral joints present smooth osseous margins and congruent joint spaces. The femora are incompletely extended.

RADIOGRAPHIC DIAGNOSIS

Left elbow

- Coronoid pathology
- Medial epicondylar spur

Left shoulder

- Possible OCD
- Muscle atrophy along humerus

Right elbow

- Soft tissue swelling, severe



PATIENT

Briggs Scott

SPECIES

Canine

BREED

Border Collie

SEX

Neutered Male

AGE

10 Years

WEIGHT

52.4 pounds

INTERPRETED BY

Heike Rudorf, DVM, Dr. med. Vet., DipECVDDI
DVR

IMAGING PERFORMED BY

Kevin & Katy

HOSPITAL NAME

Elizabeth Animal Hospital

REFERRING VET

Dr. Kim Allyn DVM

INVOICE

14518

DATE

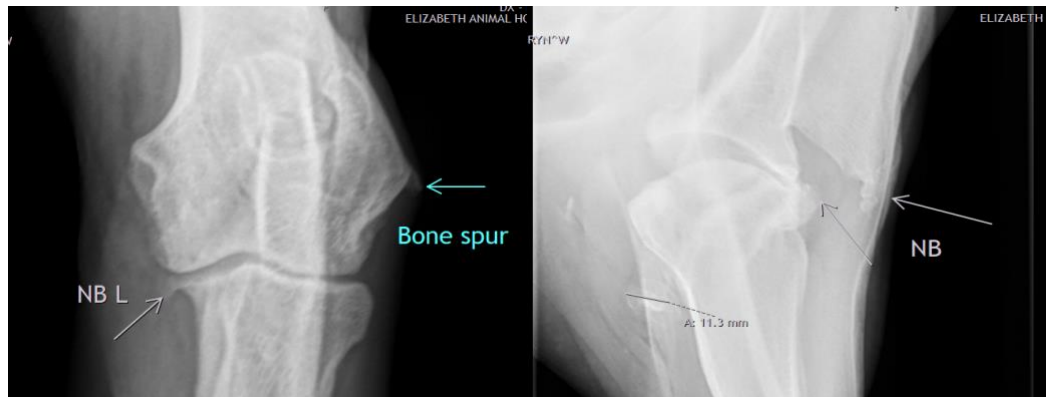
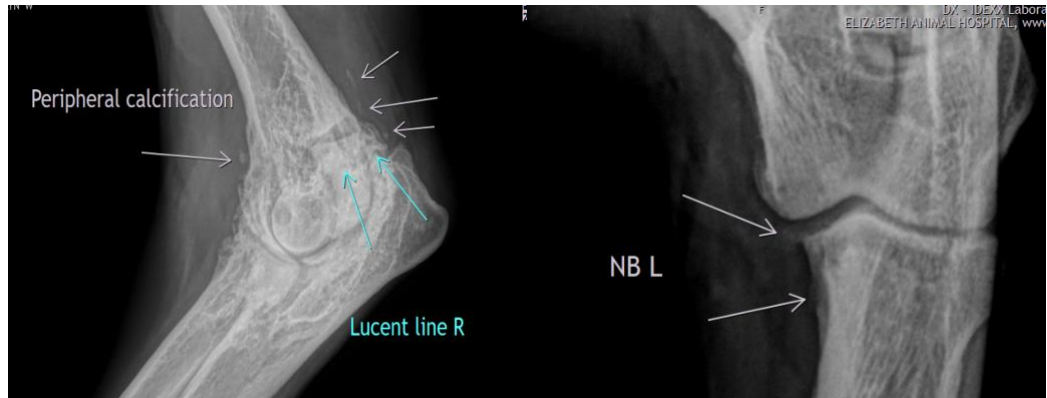
03/20/25

- Arthrosis, severe
- UAP

INTERPRETATION OF THE FINDINGS & FURTHER RECOMMENDATIONS

The changes in the right elbow joint are severe and likely due to an ununited anconeal process. The changes on the left indicate coronoid pathology and the epicondylar spur could be associated with flexor myopathy. Shoulder OCD would explain the calcified fragment. This combination may be causing the muscle atrophy, but neuropathy of the brachial plexus should be considered, and cross-sectional imaging is recommended to rule out brachial plexus tumor/neuritis. Joints and flexor muscles can be assessed in the same examination. I can see no bony cause for the inability to extend the hind legs fully. The decreased muscle mass could be due to disc disease or neuropathy, and cross-sectional imaging is suggested here as well.

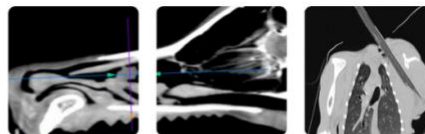
No side marker VD pelvis.



The information and recommendations provided are based on the images presented by the referring veterinarian/sonographer. No evaluation can be communicated regarding pathology that was not visible in the image/video clips provided.

Thank you for this referral. If the clinical or image interpretation does not parallel your findings or if I can be of any further assistance, please contact me.

Heike Rudorf, DVM, Dr. med. vet., DipECVDDI, DVR



PATIENT

info@sonopath.com

Briggs Scott

SPECIES

Canine

BREED

Border Collie

SEX

Neutered Male

AGE

10 Years

WEIGHT

52.4 pounds

INTERPRETED BY

Heike Rudolf, DVM, Dr.
med. Vet., DipECVDI
DVR

**IMAGING
PERFORMED BY**

Kevin & Katy

HOSPITAL NAME

Elizabeth Animal
Hospital

REFERRING VET

Dr. Kim Allyn DVM

INVOICE

14518

DATE

03/20/25