

**PATIENT**

Fiona Kennedy-Phayre

PRESENTING CLINICAL SIGNS

2 week history of pelvic limb weakness and discomfort when picked up. Owners noticed dribbling urine in the last 48 hours.

SPECIES

Canine

RADIOGRAPHIC STUDY OF T- AND L-SPINE

2 orthogonal views of thoracic and lumbar spine

BREED

Corgi

The surrounding muscles and fat layers appear physiological.

No compressive lesions or structural alterations are evident along the thoracic and lumbar spine.

No signs of aggressive osteolysis have been identified.

SEX

FS

The facet joints are congruent.

The disc spaces appear to be of homogeneous width. An oval increased opacity appears to be located in the T10/11 intervertebral disc space.

AGE

9.5 Years

RADIOGRAPHIC DIAGNOSIS

- Possible disc mineralization in situ T10/11

INTERPRETED BY

Heike Rudolf, DVM,
Dr. med. Vet.,
DipECVDDVR

INTERPRETATION OF THE FINDINGS & FURTHER RECOMMENDATIONS

Accurate positioning of the spine is difficult even under G.A. and cord compression can only be identified with myelography or in cross sectional imaging. CT or MRI will be necessary in case an extruded disc causes the clinical signs and needs to be removed. A lumbar plexus tumour is unlikely but will be ruled out with contrast CT or MRI. The subsequent imaging findings will have to be related to the findings of the neurological examination. Pancreatic disease can cause abdominal discomfort when being picked up and should be ruled out with a haematology profile.

HOSPITAL NAME

Tahoe Integrative
Veterinary Care

REFERRING VET

Dr. Wendy Robinson

INVOICE

50717

DATE

3-2-22



PATIENT

Fiona Kennedy-Phayre

SPECIES

Canine

BREED

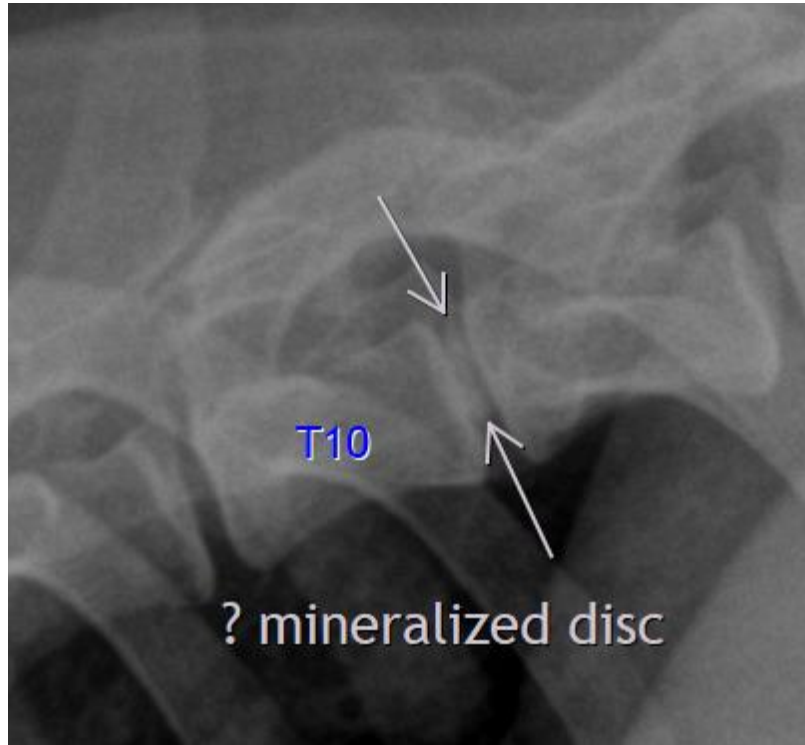
Corgi

SEX

FS

AGE

9.5 Years



INTERPRETED BY

Heike Rudorf, DVM,
Dr. med. Vet.,
DipECVDDI DVR

The information and recommendations provided are based on the images presented by the referring veterinarian/sonographer. No evaluation can be communicated regarding pathology that was not visible in the image/video clips provided.

Thank you for this referral. If the clinical or image interpretation does not parallel your findings or if I can be of any further assistance please contact me.

HOSPITAL NAME

Tahoe Integrative
Veterinary Care

Heike Rudorf, DVM, Dr. med. vet., DipECVDDI, DVR
Dr.H.Rudorf@gmail.com

REFERRING VET

Dr. Wendy Robinson

INVOICE

50717

DATE

3-2-22