



PATIENT

Samson Billie

SPECIES

Canine

BREED

Shih/poo

SEX

MN

AGE

15Y, 8M

WEIGHT

4.8lbs

INTERPRETED BY

Heike Rudolf, DVM, Dr.
med. Vet., DipECVDI
DVR

IMAGING PERFORMED BY

Erin, LVT, Jayden, VA

HOSPITAL NAME

Gentle Doctor Animal
Hospital

REFERRING VET

Dr. Nick Hayes

INVOICE

74271

DATE

3-18-26

PRESENTING CLINICAL SIGNS

Right tonsil SCC discovered while intubating for dental cleaning. Thoracic radiographs for staging.

Abnormal PE/Chem/CBC/UA Results: Histopathology confirmed right tonsil squamous cell carcinoma.

RADIOGRAPHS OF THE THORAX

R/L lateral and VD are provided, totaling three radiographs for interpretation.

RADIOGRAPHIC FINDINGS

The body condition score is 6/9 with smooth, alternating layers of fat and soft tissue opacity.

The bony structures appear physiological.

The cranial mediastinum is of physiologic size and opacity. The carina is located level with T5/6. In right lateral recumbency an approx. 0.4cm soft tissue rounded structure is located over the terminal trachea and is superimposed by two ribs.

The lung lobes are well aerated and extend to the thoracic boundaries. Pulmonary vessels are well outlined to the tertiary branches. The bronchial tree is thin walled and tapers towards the periphery.

The cardiac silhouette occupies 75% of the chest height and 3 intercostal spaces. Chamber or outflow tract enlargement is not obvious.

RADIOGRAPHIC DIAGNOSIS

- Nodular opacity in region of terminal trachea

INTERPRETATION OF THE FINDINGS & FURTHER RECOMMENDATIONS

I can see no convincing metastases or lymphadenomegaly. The nodular structure in right lateral recumbency probably highlights a main end-on vessel on the tilted view that would not be seen were the costo-chondral cartilages at the same level. Local (submandibular and retropharyngeal) and cervical lymph nodes should be checked (usually in CT) and sampled for cytological examination.



PATIENT

Samson Billie

SPECIES

Canine

BREED

Shih/poo

SEX

MN

AGE

15Y, 8M

WEIGHT

4.8lbs

INTERPRETED BY

Heike Rudolf, DVM, Dr.
med. Vet., DipECVDI
DVR

IMAGING PERFORMED BY

Erin, LVT, Jayden, VA

HOSPITAL NAME

Gentle Doctor Animal
Hospital

REFERRING VET

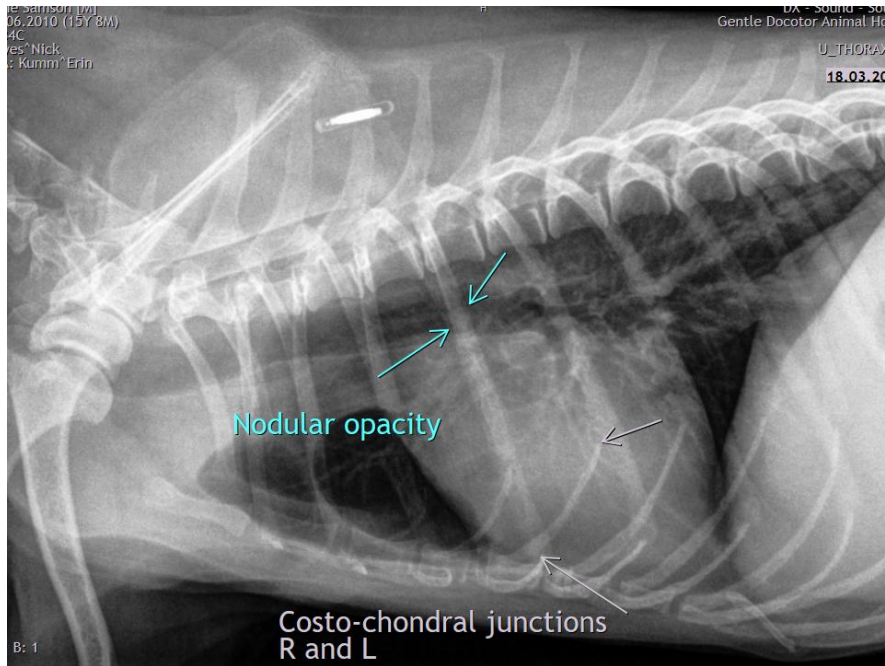
Dr. Nick Hayes

INVOICE

74271

DATE

3-18-26



The information and recommendations provided are based on the images presented by the referring veterinarian/sonographer. No evaluation can be communicated regarding pathology that was not visible in the image/video clips provided.

Thank you for this referral. If the clinical or image interpretation does not parallel your findings or if I can be of any further assistance, please contact me.

Heike Rudolf, DVM, Dr. med. vet., DipECVDI, DVR
info@sonopath.com