



**PATIENT PRESENTING CLINICAL SIGNS**

Lucas Diaz Pet is here for vax, but P has been having vomiting and diarrhea for 2 days ago.. no eating and drinking a lot water, O give chicken, rice but pet vomiting with de french food. No C/S U ok A: Gastroenteritis R/O F.B vs pancreatitis vs others

**SPECIES** Abnormal PE/Chem/CBC/UA Results: Diag- ALT 162 CBC- HCT 56.8, HGB 20.5 CPL- Normal

Canine **RADIOGRAPH OF THORAX AND ABDOMEN**

**BREED** Thorax: 2 orthogonal views  
Abdomen: 2x RLR and 1x VD views

Bulldog **RADIOGRAPHIC FINDINGS**

The body condition score is 6/9.

**SEX** Congenital vertebral anomalies are present between T5 and T9.

Male Thorax

**AGE** The lungs are in contact with the thoracic boundaries and the tips are pointed. The lobar vessels are clearly visible to the tertiary branches. The bronchial tree is thin walled and tapers uniformly towards the periphery.

1

**INTERPRETED BY** The cranial mediastinum is of physiological size and opacity. The trachea diverges from the thoracic vertebrae and the carina is located at T5. An oesophageal shadow is not evident.

Heike Rudolf, DVM,  
Dr. med. Vet.,  
DipECVDI DVR

The cardiac silhouette occupies 75% of the chest height and 3 intercostal spaces. No chamber or outflow tract enlargement is evident.

**HOSPITAL NAME** Abdomen

Animal Paradise Hospital The abdominal detail is reasonable; diaphragm and abdominal wall are intact.

The stomach is moderately filled with fluid and air; the small intestinal (SI) loops are prominent and contain mainly fluid but also some gas. In the right abdomen, the loops appear concertina shaped and stacked. Colon and rectum contain a fluid and gas.

**REFERRING VET** The other abdominal organs appear physiological.

Dr. Elshafie

**RADIOGRAPHIC DIAGNOSIS**

- INVOICE**
- Suspected linear foreign body
  - Congenital vertebral anomalies
- 50980

**INTERPRETATION OF THE FINDINGS & FURTHER RECOMMENDATIONS**

**DATE** Abdominal ultrasound is recommended to verify the stacking and to identify a linear foreign object. A Barium follow through can be performed and the 24-hour film will show Barium adherent to a linear object. Alternatively, 2 orthogonal views of the abdomen should be repeated and if the SI loops show a similar arrangement, surgery is recommended. The base of the tongue

3-16-22



**PATIENT**

will have to be checked in case the foreign body is embedded there or is wrapped around it.

Lucas Diaz

A sliding hiatal hernia, which frequently occurs in the BOAS breeds, should be ruled out with oesophagoscopy.

**SPECIES**

Canine

**BREED**

Bulldog

**SEX**

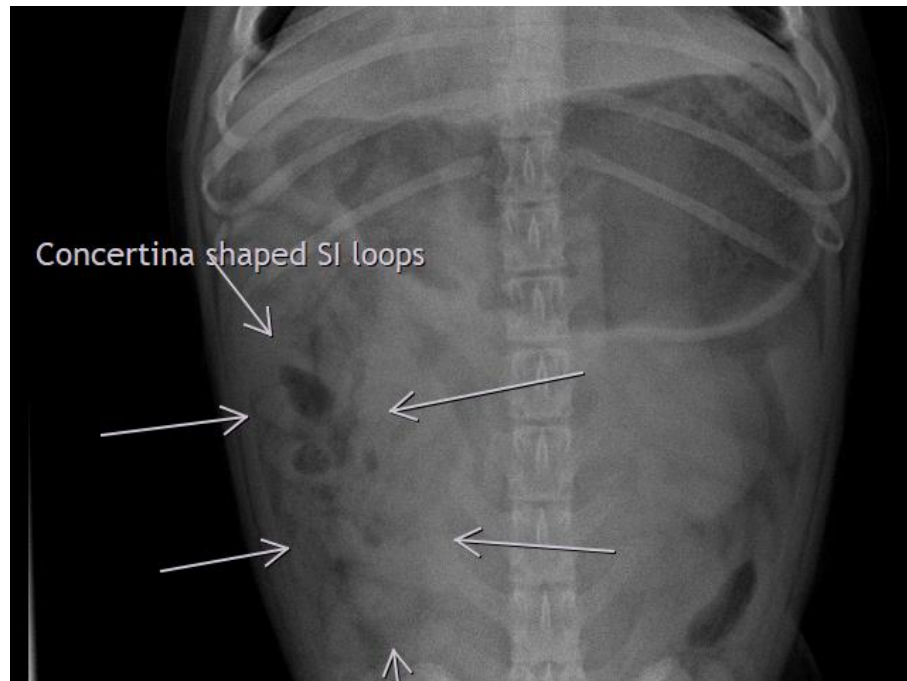
Male

**AGE**

1

**INTERPRETED BY**

Heike Rudolf, DVM,  
Dr. med. Vet.,  
DipECVDDI DVR



**HOSPITAL NAME**

Animal Paradise  
Hospital

The information and recommendations provided are based on the images presented by the referring veterinarian/sonographer. No evaluation can be communicated regarding pathology that was not visible in the image/video clips provided.

**REFERRING VET**

Dr. Elshafie

Thank you for this referral. If the clinical or image interpretation does not parallel your findings or if I can be of any further assistance please contact me.

**Heike Rudolf**, DVM, Dr. med. vet., DipECVDDI, DVR  
Dr.H.Rudorf@gmail.com

**INVOICE**

50980

**DATE**

3-16-22