



<b>PATIENT</b>	<b>PRESENTING CLINICAL SIGNS</b>
Charlie Hastings	Patient presented for acute limping for last 4 days, owner not sure what happened. Rimadyl has not helped. Intermittent toe touching lame, grade III luxating patella, could not appreciate cranial drawer
<b>SPECIES</b>	<b>RADIOGRAPHIC STUDY OF PELVIS AND STIFLES</b>
Canine	2x VD pelvis, R and L lat. stifle
<b>BREED</b>	<b>RADIOGRAPHIC FINDINGS</b>
Jack Russell	The muscle mass of the gastrocnemius appears slightly reduced on the left leg.  All bones are well mineralized, have a normal trabecular structure and a smooth surface. Cortical-medullary development and differentiation of the long bones are physiological.
<b>SEX</b>	<u>Pelvis</u>
MN	The centre of both femoral heads is located medial to the respective dorsal acetabular edge. Both hip joints appear congruent with even subchondral bone surfaces. No new bone formation is evident.
<b>AGE</b>	<u>Stifles</u>
7 Years	Both stifle joints have smooth subchondral bone surfaces, and the centre of the femoral condyles is in line with the intercondylar eminence. The cranial fat pad has a physiological size, and the caudal fascial plains are in a physiological position. A small amount of new bone formation runs along the distolateral aspect of the left lateral condyle and along the entire right lateral condyle. The tip of both patellae shows new bone formation and is more pronounced on the right. Both patellae are located in their respective groove.
<b>INTERPRETED BY</b>	<b>RADIOGRAPHIC DIAGNOSIS</b>
Heike Rudolf, DVM, Dr. med. Vet., DipECVDI DVR	<ul style="list-style-type: none"> <li>• Bilateral stifle OA, mild</li> <li>• Possible mild asymmetry of gastrocnemius muscles</li> </ul>
<b>HOSPITAL NAME</b>	<b>INTERPRETATION OF THE FINDINGS &amp; FURTHER RECOMMENDATIONS</b>
Boca Park Animal Hospital	I can see no cause for the acute and severe lameness. The slight size difference of the gastrocnemius muscles may have been caused by a slightly different leg position. The stifle OA is most likely associated with the patella luxation identified during palpation. A severe lameness without response to pain killers could be due to a foreign body in the toe region or can be caused by a hairline fissure in the digits. Ultrasound is suggested if pain is located in a pad and a DP radiograph of the paw if a particular digit appears to be painful; it can take up to 7 days before the line is large enough to be appreciated. Alternatively, a traumatic neuropathy could be causing the lameness and cross-sectional imaging may have to follow a neurological examination.
<b>REFERRING VET</b>	
Dr. Corinna Gorgon	
<b>INVOICE</b>	
50978	
<b>DATE</b>	
3-16-22	



**PATIENT**

Charlie Hastings

**SPECIES**

Canine

**BREED**

Jack Russell

**SEX**

MN

**AGE**

7 Years

**INTERPRETED BY**

Heike Rudorf, DVM,  
Dr. med. Vet.,  
DipECVDI DVR

**HOSPITAL NAME**

Boca Park Animal  
Hospital

**REFERRING VET**

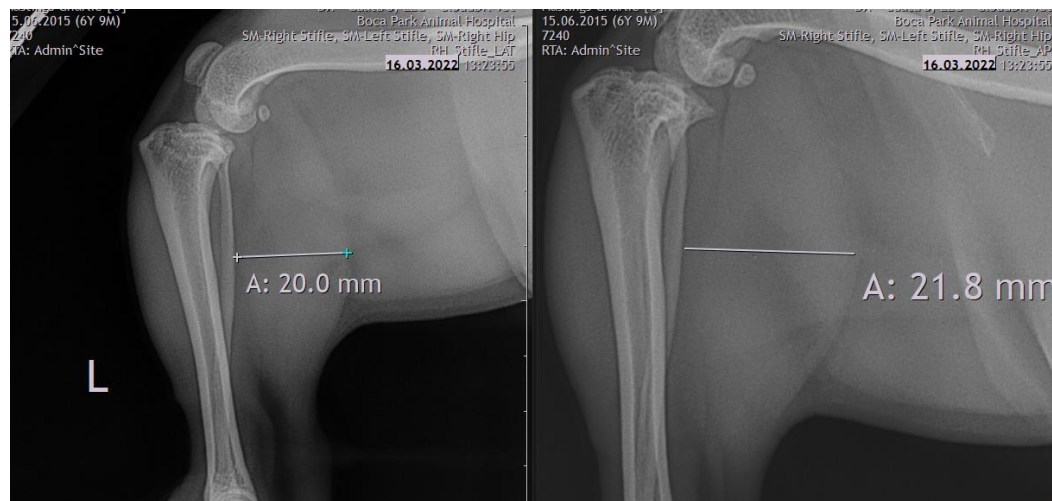
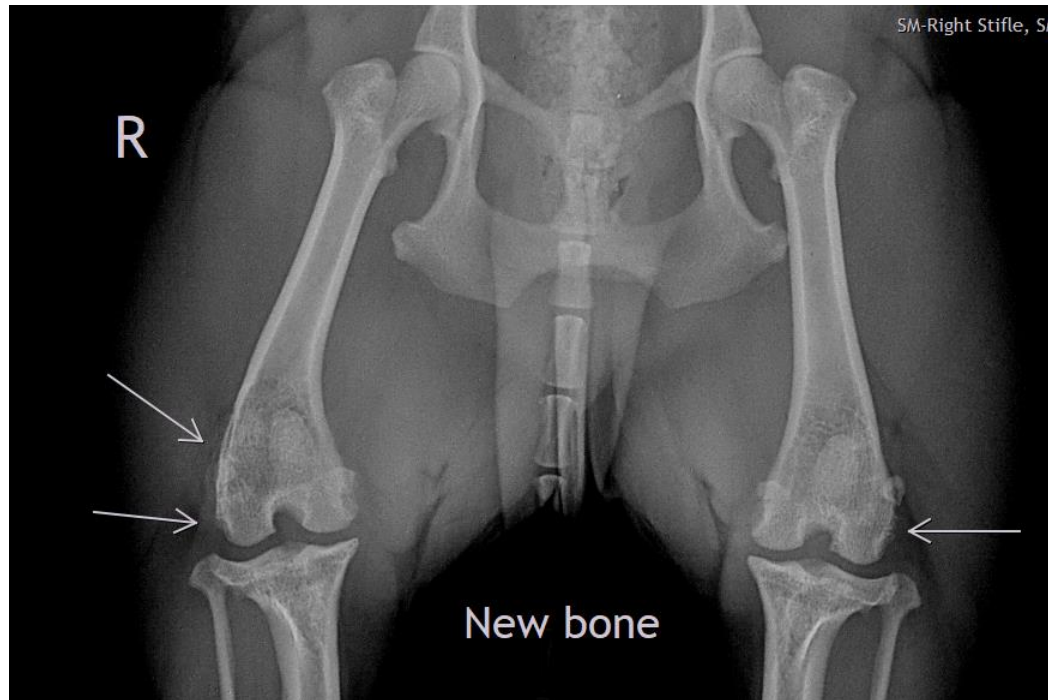
Dr. Corinna Gorgon

**INVOICE**

50978

**DATE**

3-16-22





**PATIENT**

Charlie Hastings

The information and recommendations provided are based on the images presented by the referring veterinarian/sonographer. No evaluation can be communicated regarding pathology that was not visible in the image/video clips provided.

Thank you for this referral. If the clinical or image interpretation does not parallel your findings or if I can be of any further assistance please contact me.

**SPECIES**

Canine

**Heike Rudolf**, DVM, Dr. med. vet., DipECVDI, DVR  
Dr.H.Rudorf@gmail.com

**BREED**

Jack Russell

**SEX**

MN

**AGE**

7 Years

**INTERPRETED BY**

Heike Rudolf, DVM,  
Dr. med. Vet.,  
DipECVDI DVR

**HOSPITAL NAME**

Boca Park Animal  
Hospital

**REFERRING VET**

Dr. Corinna Gorgon

**INVOICE**

50978

**DATE**

3-16-22