



**PATIENT PRESENTING CLINICAL SIGNS**

Nacho Tracy Dog was seen in March for coughing, diagnosed with probable collapsing trachea and chronic old dog lung changes, possible chronic bronchitis by Dr. Cheeseman here. She did very well on Tamaril P, but cough recurred within a week or two of finishing the medication. She coughs intermittently, maybe 3 times per week, but when she does, it can go on for 3-5 minutes. Does happen sometimes with excitement, but can also happen when she is just resting. Was rechecked in May and recommendations were made for a dental which was performed. No improvement and the cough appears to be progressing. Exam today no wheezes, crackles, or murmur auscultated. no response to tracheal pinch

**SPECIES**

Canine

**BREED**

Chihuahua

**RADIOGRAPHIC STUDY OF THE THORAX**

The body condition score is 7/9.

Small osteophytes are present on the cranial thoracic end plates of T8 and T9.

**SEX**

FS

The degree of pulmonary expansion is fair but, on the VD view, the lobar vessels are visible to the tertiary branches. The bronchial tree is thin walled and tapers uniformly towards the periphery. The lungs are in contact with the thoracic boundaries and the tips are pointed.

**AGE**

14

The cranial mediastinum is of physiological size and opacity. The trachea runs parallel to the thoracic vertebrae and dips at the carina. In left lateral recumbency the air shadow in the caudal cervical trachea is, compared to the thoracic trachea, severely reduced in height due to a dorsal soft tissue opacity (0.3cm vs 0.8cm).

**INTERPRETED BY**

Heike Rudolf, DVM,  
Dr. med. Vet.,  
DipECVDI DVR

The cardiac silhouette occupies 85% of the chest height and approx. 3 intercostal spaces, the cranial heart border is not clearly outlined on the right lateral recumbent views (VHS 10). On the VD view the pulmonary artery segment is just visible and the right side as well as the region of the left ventricle are rounded; cardiac in relation to thoracic width is physiological.

The stomach is moderately filled with food and the gastric axis is slightly rotated caudally.

**HOSPITAL NAME**

Valley Veterinary  
Services

**RADIOGRAPHIC DIAGNOSIS**

- Collapsing trachea
- Incidental findings:
- Hepatomegaly, mild
  - Ventral spondylosis, minimal

**REFERRING VET**

Korin D'Ascenzo

**INTERPRETATION OF THE FINDINGS & FURTHER RECOMMENDATIONS**

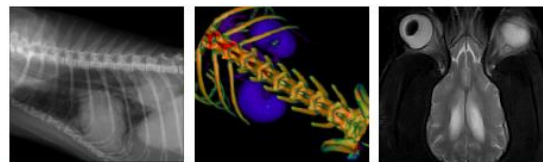
Tracheal collapse can be due to a weakened dorsal tracheal ligament; it can occur in combination with bronchial collapse Both can go unnoticed until physical circumstances (such as stress, running, excitement) or disease (e.g. pneumonia, bronchitis, L cardiac enlargement) reduces the ease of airflow. Bronchitis can be present without radiographic signs, thus tracheo-bronchoscopy with broncho-alveolar lavage is recommended. Echocardiography will give a baseline of cardiac function and valvular regurgitation because endocardiosis is common in small breed dogs. In case liver enzymes are elevated, ruling out Cushing's disease is recommended.

**INVOICE**

59778

**DATE**

3-14-23



**PATIENT**

Nacho Tracy

**SPECIES**

Canine

**BREED**

Chihuahua

**SEX**

FS

**AGE**

14

**INTERPRETED BY**

Heike Rudorf, DVM,  
Dr. med. Vet.,  
DipECVDDI DVR

**HOSPITAL NAME**

Valley Veterinary  
Services

**REFERRING VET**

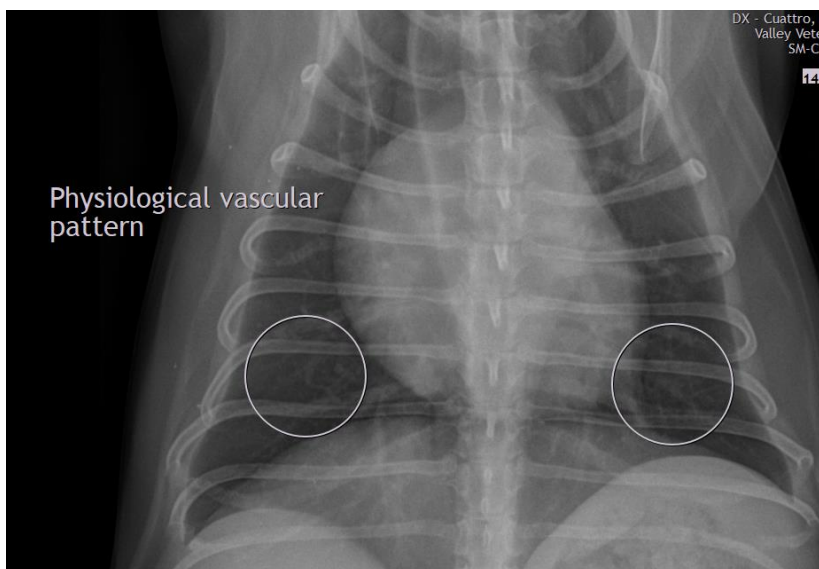
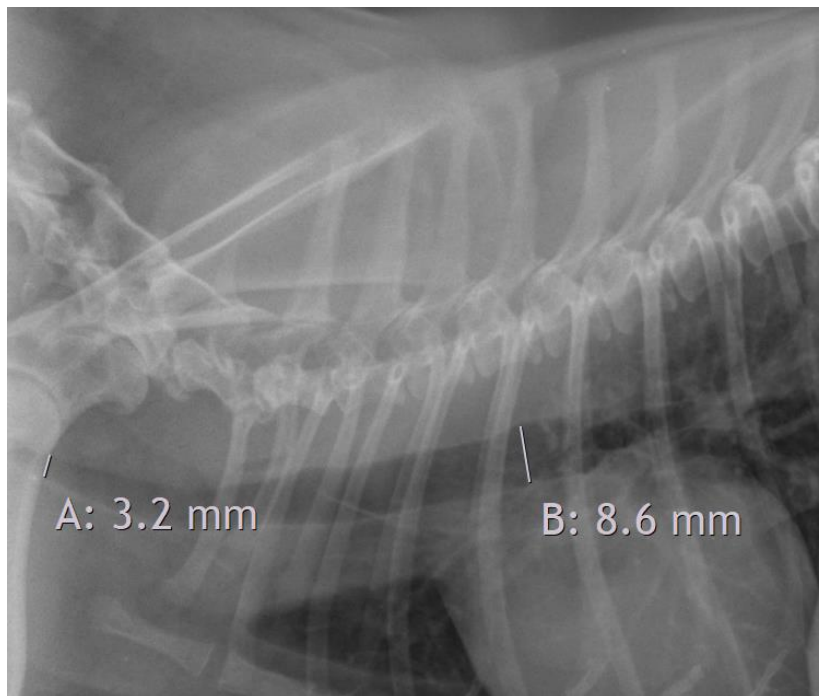
Korin D'Ascenzo

**INVOICE**

59778

**DATE**

3-14-23





**PATIENT**

Nacho Tracy

The information and recommendations provided are based on the images presented by the referring veterinarian/sonographer. No evaluation can be communicated regarding pathology that was not visible in the image/video clips provided.

Thank you for this referral. If the clinical or image interpretation does not parallel your findings or if I can be of any further assistance please contact me.

**SPECIES**

Canine

**Heike Rudolf**, DVM, Dr. med. vet., DipECVDI, DVR  
Dr.H.Rudorf@gmail.com

**BREED**

Chihuahua

**SEX**

FS

**AGE**

14

**INTERPRETED BY**

Heike Rudolf, DVM,  
Dr. med. Vet.,  
DipECVDI DVR

**HOSPITAL NAME**

Valley Veterinary  
Services

**REFERRING VET**

Korin D'Ascenzo

**INVOICE**

59778

**DATE**

3-14-23