

PATIENT

Zelda Yenko

SPECIES

Canine

BREED

German Shepherd

SEX

Spayed Female

AGE

3 Years 9 Months

WEIGHT

71 pounds

INTERPRETED BY

Heike Rudolf, DVM, Dr.
med. Vet., DipECVDDI
DVR

IMAGING PERFORMED BY

Katy

HOSPITAL NAME

Elizabeth Animal
Hospital

REFERRING VET

Dr. Kim Allyn DVM

INVOICE

14330

DATE

03/13/26

PRESENTING CLINICAL SIGNS

Had a fractured MC 4 on her right forelimb a month ago after getting clipped by a golf club

4 weeks of splint bandages

Progress check of healing

RADIOGRAPHIC STUDY OF THE CARPI

R lateral and DP, totaling 2 radiographs provided for interpretation.

13.03.2026

RADIOGRAPHIC FINDINGS

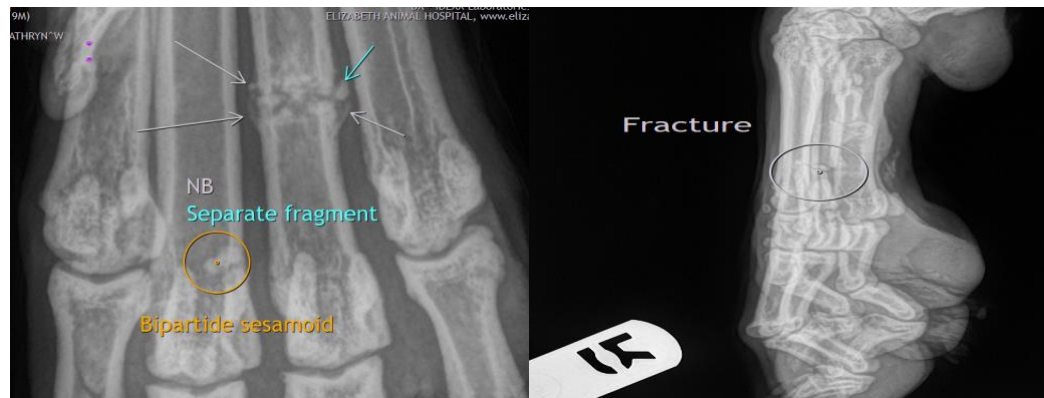
Mc 4: a radiolucent line traverses from the lateral to the medial cortex of the distal Mc bone. Bridging new bone is present along both cortices and seems to obscure the fracture line slightly. Criss-crossing lucent lines are adjacent to the fracture line. A smoothly delineated fragment is located on the lateral cortex.

RADIOGRAPHIC DIAGNOSIS

- Mc 4 transverse fracture: healing in progress
- Sesamoid 4: bipartite

INTERPRETATION OF THE FINDINGS & FURTHER RECOMMENDATIONS

Bridging new bone is present along well alignment cortices. The fracture line is still visible. These views should be compared with the original images to allow a prognosis.



The information and recommendations provided are based on the images presented by the referring veterinarian/sonographer. No evaluation can be communicated regarding pathology that was not visible in the image/video clips provided.

Thank you for this referral. If the clinical or image interpretation does not parallel your findings or if I can be of any further assistance, please contact me.

Heike Rudolf, DVM, Dr. med. vet., DipECVDDI, DVR

info@sonopath.com