



PATIENT PRESENTING CLINICAL SIGNS

PATIENT Yoda Opsteadl History: Presented for acute onset of V/D and unwillingness to walk. O reports P and housemates (larger breeds) got into some left over Chinese food and dumplings last evening. Approx 2-3 hours later P vomited 2-3 times entire stomach contents and had an episode of diarrhea. O reports P also took a big jump down from the bed while she was attempting to vomit and may have injured her leg. She typically uses stairs and has not been wanting to walk or ambulate well.

SPECIES

Canine

BREED

Chihuahua

Abnormal PE/Chem/CBC/UA Results: CBC - WNL Comprehensive - GLOB 1.6 (2.3-5.2) cPL - Normal range.

RADIOGRAPHIC STUDY OF THE L-SPINE

The surrounding soft tissue and fat layers appear physiological.

SEX

Neutered Male

Number and shape of the vertebrae are physiological. The skeletal structures are well mineralized and have smooth surfaces. No compressive lesions or structural alterations are evident along the lumbar spine. No signs of aggressive osteolysis have been identified.

AGE

11 Years

The facet joints are congruent.

On the lateral views the caudal endplates are overlapping the disc spaces between T13 and S1.

RADIOGRAPHIC DIAGNOSIS

- I can see no obvious spinal pathology

INTERPRETED BY

Heike Rudolf, DVM,
Dr. med. Vet.,
DipECVDI DVR

INTERPRETATION OF THE FINDINGS & FURTHER RECOMMENDATIONS

Accurate positioning of the spine is difficult even under G.A. and cord compression can only be identified with myelography or in cross sectional imaging. Depending on the severity of the clinical signs, CT or MRI will be necessary in case an extruded disc needs to be removed.

HOSPITAL NAME

Boca Park AH

REFERRING VET

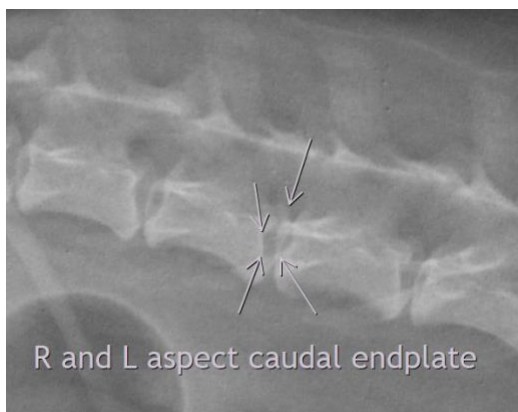
Dr. Ashman

INVOICE

14293

DATE

3/11/22





PATIENT

Yoda Opsteadl

The information and recommendations provided are based on the images presented by the referring veterinarian/sonographer. No evaluation can be communicated regarding pathology that was not visible in the image/video clips provided.

SPECIES

Canine

Thank you for this referral. If the clinical or image interpretation does not parallel your findings or if I can be of any further assistance please contact me.

Heike Rudolf, DVM, Dr. med. vet., DipECVDI, DVR
dr.h.rudorf@gmail.com

BREED

Chihuahua

SEX

Neutered Male

AGE

11 Years

INTERPRETED BY

Heike Rudolf, DVM,
Dr. med. Vet.,
DipECVDI DVR

HOSPITAL NAME

Boca Park AH

REFERRING VET

Dr. Ashman

INVOICE

14293

DATE

3/11/22