



PATIENT PRESENTING CLINICAL SIGNS

Jack Brito History: Difficulty getting up

RADIOGRAPHIC STUDY OF L-SPINE AND STIFLES

SPECIES

Canine The surrounding muscles and fat layers appear physiological.

No compressive lesions or structural alterations are evident along the thoracic and lumbar spine. No signs of aggressive osteolysis have been identified. Number and shape of the L-vertebrae are physiological. A dorsal deviation of the sacro-coccygeal junction is present.

BREED

Mini Pin The facet joints appear to be congruent.

SEX

The disc spaces L3-L6 show the edge of one side of the caudal endplate.

Neutered Male

Stifles

The right stifle joint has smooth subchondral bone surfaces, and the centre of the femoral condyles is in line with the intercondylar eminence. The cranial fat pad appears to have a physiological size and the caudal fascial plains appear to be in a physiological position. New bone formation is not evident, and the patella is located cranial to the femoral ridges.

AGE

9 Years

The left stifle joint has smooth subchondral bone surfaces, and the centre of the femoral condyles is in line with the intercondylar eminence. The cranial fat pad appears increased in opacity and the caudal fascial plains are not visible. New bone formation is not evident.

INTERPRETED BY

Heike Rudolf, DVM,
Dr. med. Vet.,
DipECVDI DVR

RADIOGRAPHIC DIAGNOSIS

- Possible cruciate disease left stifle

HOSPITAL NAME

New Bridge VP

INTERPRETATION OF THE FINDINGS & FURTHER RECOMMENDATIONS

Loss of the caudal fascial plains suggest joint effusion. Manual examination will help identify a cranial drawer though sometimes this is only evident under deep sedation. Patella luxation is often not visible on lateral radiographs. An imaging diagnosis of a patella luxation is best made in a skyline view of the flexed stifle. This will also allow assessment of the femoral ridges.

REFERRING VET

Dr. Abina Glennon

Accurate positioning of the spine is difficult even under G.A. and cord compression can only be identified with myelography or in cross sectional imaging. Depending on the severity of the clinical signs and findings during the neurological examination, CT or MRI will be necessary in case an extruded disc needs to be removed.

INVOICE

14294

TECHNICAL COMMENTS

DATE

Oblique left stifle.

3/12/22



PATIENT

Jack Brito

SPECIES

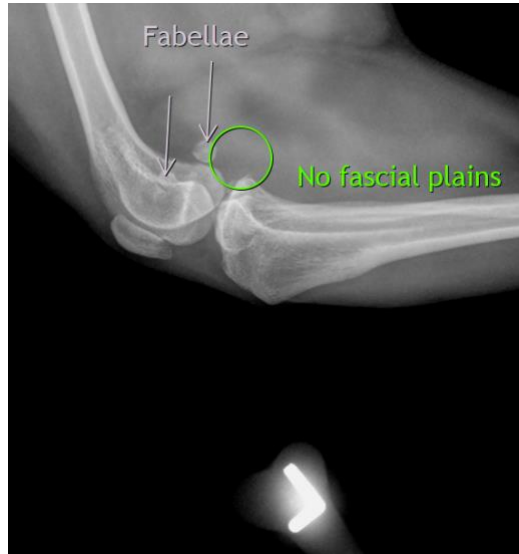
Canine

BREED

Mini Pin

SEX

Neutered Male



AGE

9 Years

The information and recommendations provided are based on the images presented by the referring veterinarian/sonographer. No evaluation can be communicated regarding pathology that was not visible in the image/video clips provided.

Thank you for this referral. If the clinical or image interpretation does not parallel your findings or if I can be of any further assistance please contact me.

INTERPRETED BY

Heike Rudorf, DVM,
Dr. med. Vet.,
DipECVDI DVR

Heike Rudorf, DVM, Dr. med. vet., DipECVDI, DVR
dr.h.rudorf@gmail.com

HOSPITAL NAME

New Bridge VP

REFERRING VET

Dr. Abina Glennon

INVOICE

14294

DATE

3/12/22