



PATIENT PRESENTING CLINICAL SIGNS

PATIENT Hugo Richard
SPECIES Canine
BREED Yorkshire Terrier Mix
SEX Male
AGE 13 Weeks

History: Started coughing 2 weeks ago. At the beginning it was more dry cough, now getting more moist. On March 1, 2023 dewormed and prescribed Clavamox liquid antibiotic. The owner was supposed to come 3 days ago for a recheck, came today, and the dog is still and more frequently coughing. Normal eating and drinking, normal energy level. No any diarrheas. Today vomited after coughing.

RADIOGRAPHIC STUDY OF THE THORAX

The body condition score is 7/9 with smooth alternating layers of fat and soft tissue opacity.

The bony structures appear physiological.

The lungs are in contact with the thoracic boundaries and the tips are pointed. The outline of the peripheral lobar vessels is slightly blurred. The bronchial walls appear prominent, especially in the left lung, and resemble tramlines.

The cranial mediastinum is of physiological size and opacity. The trachea diverges from the thoracic vertebrae and dips at the carina.

The cardiac silhouette occupies 75% of the chest height and 3 intercostal spaces (VHS 10). No chamber or outflow tract enlargement is evident.

RADIOGRAPHIC DIAGNOSIS

- Broncho-interstitial pattern

INTERPRETED BY INTERPRETATION OF THE FINDINGS & FURTHER RECOMMENDATIONS

INTERPRETED BY Heike Rudolf, DVM, Dr. med. Vet., DipECVDDI DVR

The most likely underlying cause is interstitial pneumonia which, in immature patients, is likely to either be due to canine infectious respiratory disease and Bordetella, parainfluenza, herpes, or mycoplasma. Another potential differential diagnosis that should be considered is canine distemper. The bronchial component could be caused by an allergic reaction, e.g. if the owners are smoking.

HOSPITAL NAME St. Catharine's AH

Empirical treatment should be initiated. Only if the patient remains unresponsive to empirical treatment, further evaluation by means of tracheobronchoscopy with bronchoalveolar lavage could be considered.

REFERRING VET

Dr. Dragan Guni

INVOICE

21582

DATE

3/10/23



PATIENT

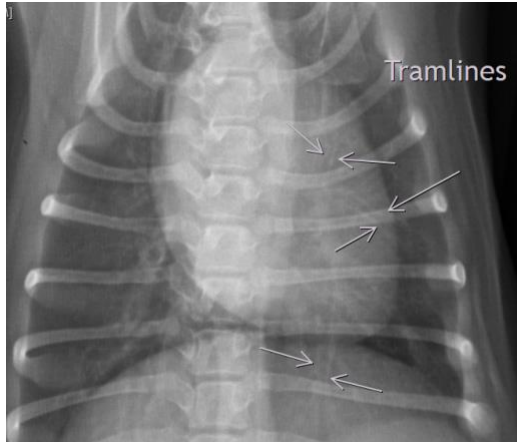
Hugo Richard

SPECIES

Canine

BREED

Yorkshire Terrier Mix



SEX

Male

AGE

13 Weeks

The information and recommendations provided are based on the images presented by the referring veterinarian/sonographer. No evaluation can be communicated regarding pathology that was not visible in the image/video clips provided.

Thank you for this referral. If the clinical or image interpretation does not parallel your findings or if I can be of any further assistance please contact me.

Heike Rudorf, DVM, Dr. med. vet., DipECVDI, DVR
dr.h.rudorf@gmail.com

INTERPRETED BY

Heike Rudorf, DVM,
Dr. med. Vet.,
DipECVDI DVR

HOSPITAL NAME

St. Catharine's AH

REFERRING VET

Dr. Dragan Guni

INVOICE

21582

DATE

3/10/23