



PATIENT

Willa June Leitner

SPECIES

Canine

BREED

Pompoop

SEX

Spayed Female

AGE

10 Months

WEIGHT

13

INTERPRETED BY

Heike Rudolf, DVM, Dr.
med. Vet., DipECVDI
DVR

IMAGING PERFORMED BY

Taren Denny,
LVT/Amanda C

HOSPITAL NAME

Gentle Doctor AH

REFERRING VET

Dr. Nicholas Hayes

INVOICE

35767

DATE

2/7/26

PRESENTING CLINICAL SIGNS

History: Chronic coughing (4 weeks) with several series of x-rays indicating bronchitis.

Patient is not responding to Termail-P and Doxycycline.

RADIOGRAPHIC STUDY OF THE THORAX

The body condition score is 7-8/9 with smooth, alternating layers of fat and soft tissue opacity.

The bony structures appear physiological.

The cranial mediastinum is of physiologic size and opacity. The trachea diverges from the thoracic vertebrae, and the carina is located level with T5.

The degree of pulmonary expansion is good.

The lung lobes are well aerated and extend to the thoracic boundaries. Pulmonary vessels are well outlined to the tertiary branches in right lateral recumbency and on the VD. The bronchial tree is thin walled and tapers towards the periphery; one small doughnut is visible level with rib 6 on the left.

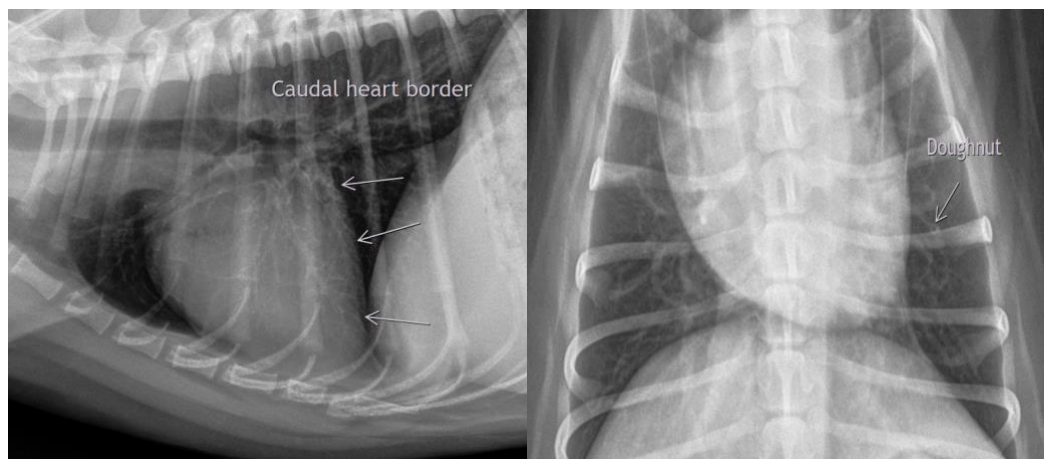
The cardiac silhouette occupies 75% of the chest height and 3 intercostal spaces. The caudal heart border appears slightly straight.

RADIOGRAPHIC DIAGNOSIS

- Possible L cardiomegaly
- Very mild increase in bronchial marking

INTERPRETATION OF THE FINDINGS & FURTHER RECOMMENDATIONS

I can see no convincing signs that would explain the cough. Bronchitis (e.g., infectious, eosinophilic) can be present without or very little radiographic evidence. Tonsillar enlargement and laryngeal disease can be ruled out prior to intubation. Tracheal and bronchi collapse can be identified prior to a broncho-alveolar lavage; samples should be submitted for bacteriological and cytological examination. Echocardiography to assess cardiac function and valvular appearance is suggested in case atrial enlargement compresses the carina.



The information and recommendations provided are based on the images presented by the referring veterinarian/sonographer. No evaluation can be communicated regarding pathology



PATIENT

Willa June Leitner

SPECIES

Canine

BREED

Pompoo

SEX

Spayed Female

AGE

10 Months

WEIGHT

13

INTERPRETED BY

Heike Rudolf, DVM, Dr.
med. Vet., DipECVDI
DVR

**IMAGING
PERFORMED BY**

Taren Denny,
LVT/Amanda C

HOSPITAL NAME

Gentle Doctor AH

REFERRING VET

Dr. Nicholas Hayes

INVOICE

35767

DATE

2/7/26

that was not visible in the image/video clips provided.

Thank you for this referral. If the clinical or image interpretation does not parallel your findings or if I can be of any further assistance, please contact me.

Heike Rudolf, DVM, Dr. med. vet., DipECVDI, DVR

info@sonopath.com