



PATIENT

Teddy Yang

SPECIES

Canine

BREED

Shih Tzu Mix

SEX

Neutered Male

AGE

12 Years

WEIGHT

7.3 kg

INTERPRETED BY

Heike Rudorf, DVM, Dr.
med. Vet., DipECVDI
DVR

IMAGING PERFORMED BY

CJ/EH

HOSPITAL NAME

The Collegeway AH

REFERRING VET

Dr. Ehab Hanna

INVOICE

35766

DATE

2/7/26

PRESENTING CLINICAL SIGNS

History: Coughing

RADIOGRAPHIC STUDY OF THE THORAX

The body condition score is 6/9 with smooth, alternating layers of fat and soft tissue opacity.

The manubrium sterni is short

The cranial mediastinum is of physiologic size and opacity. The trachea runs parallel to the thoracic vertebrae, and the carina is in line with the trachea. The tracheal lumen appears slightly reduced from dorsally in the thoracic inlet.

The degree of pulmonary expansion is fair. The lung lobes extend to the thoracic boundaries. Pulmonary vessels are well outlined to the tertiary branches. The main bronchi are well demarcated by vascular structures on both lateral views.

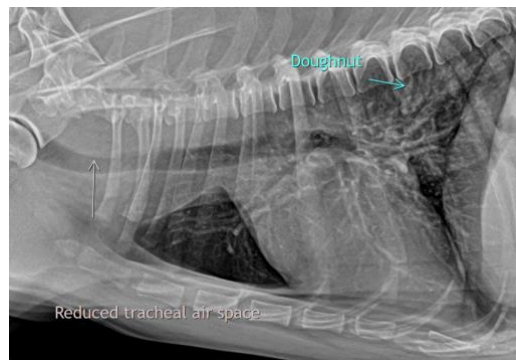
The cardiac silhouette occupies 85% of the chest height and 3 intercostal spaces. Chamber or outflow tract enlargement is not obvious.

RADIOGRAPHIC DIAGNOSIS

- Possible tracheal collapse
- Few doughnuts

INTERPRETATION OF THE FINDINGS & FURTHER RECOMMENDATIONS

Tracheal collapse alone can be due to a weakened dorsal tracheal ligament. Tracheal in combination with bronchial collapse is usually due to an altered cartilage development which may go unnoticed until physical circumstances (such as stress, running, excitement) or disease (e.g., pneumonia, bronchitis, L cardiac enlargement) reduces the ease of airflow. The gold standard for imaging both pathologies is tracheo-bronchoscopy. A sample should be obtained for cytology and bacteriology because bronchitis can be present without radiographic evidence. Echocardiography to assess cardiac function and valvular appearance is suggested. Should an underlying disease be present treatment may improve the clinical signs.





PATIENT

Teddy Yang

SPECIES

Canine

BREED

Shih Tzu Mix

SEX

Neutered Male

AGE

12 Years

WEIGHT

7.3 kg

INTERPRETED BY

Heike Rudolf, DVM, Dr.
med. Vet., DipECVDI
DVR

IMAGING PERFORMED BY

CJ/EH

HOSPITAL NAME

The Collegeway AH

REFERRING VET

Dr. Ehab Hanna

INVOICE

35766

DATE

2/7/26

The information and recommendations provided are based on the images presented by the referring veterinarian/sonographer. No evaluation can be communicated regarding pathology that was not visible in the image/video clips provided.

Thank you for this referral. If the clinical or image interpretation does not parallel your findings or if I can be of any further assistance, please contact me.

Heike Rudolf, DVM, Dr. med. vet., DipECVDI, DVR
info@sonopath.com