



**PATIENT PRESENTING CLINICAL SIGNS**

Lulu Silva client slipped and on the way down hit Lulu, Lula can't stand/walk  
 Abnormal PE/Chem/CBC/UA Results: left side head tilt , Left front & back legs very stiff and hyperextended , proprioceptive positioning normal but not able to stand ,bloodwork showed hyperphosphatemia

**SPECIES**

Canine

**RADIOGRAPHIC STUDY OF THE C- AND L-SPINE**

R, L and VD dogogram (head to stifles), 2x C-spine

**BREED**

Mini Pinscher

**RADIOGRAPHIC FINDINGS**

A smooth radiolucent line with a homogeneous width is present on one of the lateral C-spine views and crosses from the mid-ventral vertebral body of C5 caudo-dorsally. This results in the impression of a slightly cranio-ventrally displaced caudal fragment.

**SEX**

Female Spayed

No compressive lesions or structural alterations are evident along the thoracic and lumbar spine on the other views.

**AGE**

22 Months

Number and shape of the vertebrae are physiological. The skeletal structures are well mineralized and have smooth surfaces. The odontoid peg appears to be in a physiological position.

**INTERPRETED BY**

Heike Rudolf, DVM,  
 Dr. med. Vet.,  
 DipECVDDI DVR

The facet joints are congruent.

The disc spaces in the lumbar region appear of reasonable width.

**RADIOGRAPHIC DIAGNOSIS**

- I can see no consistent changes

**HOSPITAL NAME**

St. Catharine's Animal Hospital

**INTERPRETATION OF THE FINDINGS & FURTHER RECOMMENDATIONS**

The lucent line in C5 on the one lateral view most likely represents a "Mach line" due to the superimposed transverse process. Accurate positioning of the spine is difficult, even under G.A., and spinal cord damage can only be identified in cross sectional imaging. Due to the severity of the clinical signs MRI is recommended to assess the spinal cord, discs and muscles. A fracture of the occipital bone would also be more obvious.

**REFERRING VET**

Dr. Masoud

**TECHNICAL COMMENTS**

Unprotected human fingers in primary beam on three views. Rotation C-spine.

**INVOICE**

50066

**DATE**

2-4-22



**PATIENT**

Lulu Silva

**SPECIES**

Canine

**BREED**

Mini Pinscher

**SEX**

Female Spayed

**AGE**

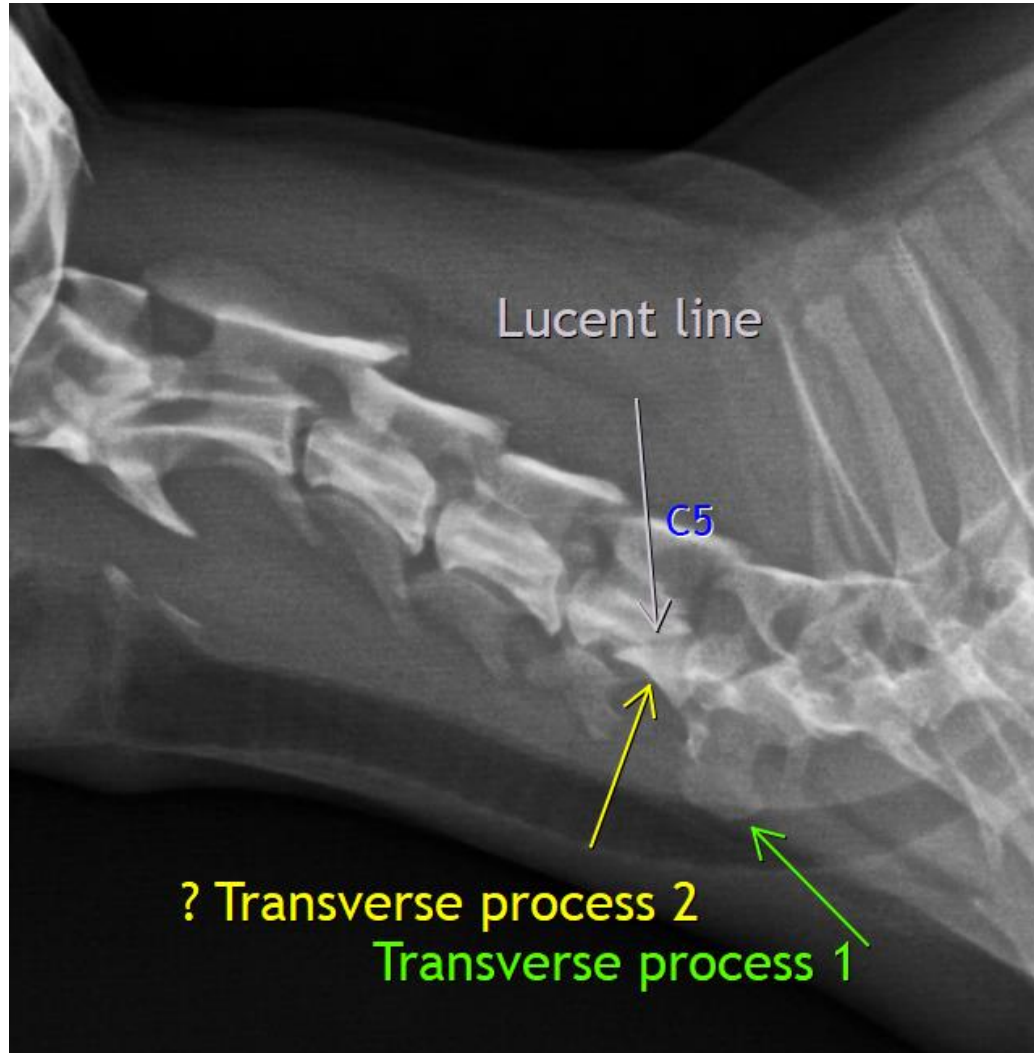
22 Months

**INTERPRETED BY**

Heike Rudorf, DVM,  
Dr. med. Vet.,  
DipECVDI DVR

**HOSPITAL NAME**

St. Catharine's Animal  
Hospital



**REFERRING VET**

Dr. Masoud

**INVOICE**

50066

**DATE**

2-4-22

The information and recommendations provided are based on the images presented by the referring veterinarian/sonographer. No evaluation can be communicated regarding pathology that was not visible in the image/video clips provided.

Thank you for this referral. If the clinical or image interpretation does not parallel your findings or if I can be of any further assistance please contact me.

**Heike Rudorf**, DVM, Dr. med. vet., DipECVDI, DVR  
Dr.H.Rudorf@gmail.com