



PATIENT	PRESENTING CLINICAL SIGNS
Harley Elliott	dog is very nervous, biter, hard to evaluate when awake. pain on hip extension , bilaterally. limps on back right leg after exercise Abnormal PE/Chem/CBC/UA Results: wnl
SPECIES	RADIOGRAPH OF THE PELVIS
Canine	1x VD pelvis, R and L lateral stifle
BREED	RADIOGRAPHIC FINDINGS
Lab Mix	The cecum is located on the right side which will be termed R in the report. The hind leg muscles are poorly developed on both sides.
SEX	Considering the tilting, the centre of both femoral heads is likely superimposed onto the respective dorsal acetabular edge. The cranial acetabular edges cover the femoral heads though the lateral joint spaces are slightly widened. New bone is present along the left femoral neck and on the right effective cranial acetabular edge. The femoral neck appears slightly thickened on the right.
MN	
AGE	All bones are well mineralized, have a normal trabecular structure and a smooth surface. Cortical-medullary development and differentiation of the long bones are physiological.
4 Years	
INTERPRETED BY	RADIOGRAPHIC DIAGNOSIS
Heike Rudorf, DVM, Dr. med. Vet., DipECVDDI DVR	<ul style="list-style-type: none">• Mild, bilateral HD• Arthrosis left hip joint more than right
HOSPITAL NAME	INTERPRETATION OF THE FINDINGS & FURTHER RECOMMENDATIONS
Maier Animal Hospital	The changes are compatible with hip dysplasia but may not represent the cause for the right sided lameness. A neurological examination is recommended in case a disc prolapse or neuropathy is present. This may have to be followed by cross sectional imaging.
REFERRING VET	TECHNICAL COMMENTS
Katie Maher	No side marker. The pelvis is tilted to the right. Only jpg images were submitted. The transformation from DICOM to jpg reduces the image quality and only allows limited manipulation of the image. More subtle lesions can thus easily be missed. For the best possible imaging reports, I suggest submitting DICOM images in the future.
INVOICE	
50081	
DATE	
2-4-22	



PATIENT

Harley Elliott

SPECIES

Canine

BREED

Lab Mix

SEX

MN

AGE

4 Years

INTERPRETED BY

Heike Rudolf, DVM,
Dr. med. Vet.,
DipECVDDI DVR

HOSPITAL NAME

Maier Animal
Hospital

REFERRING VET

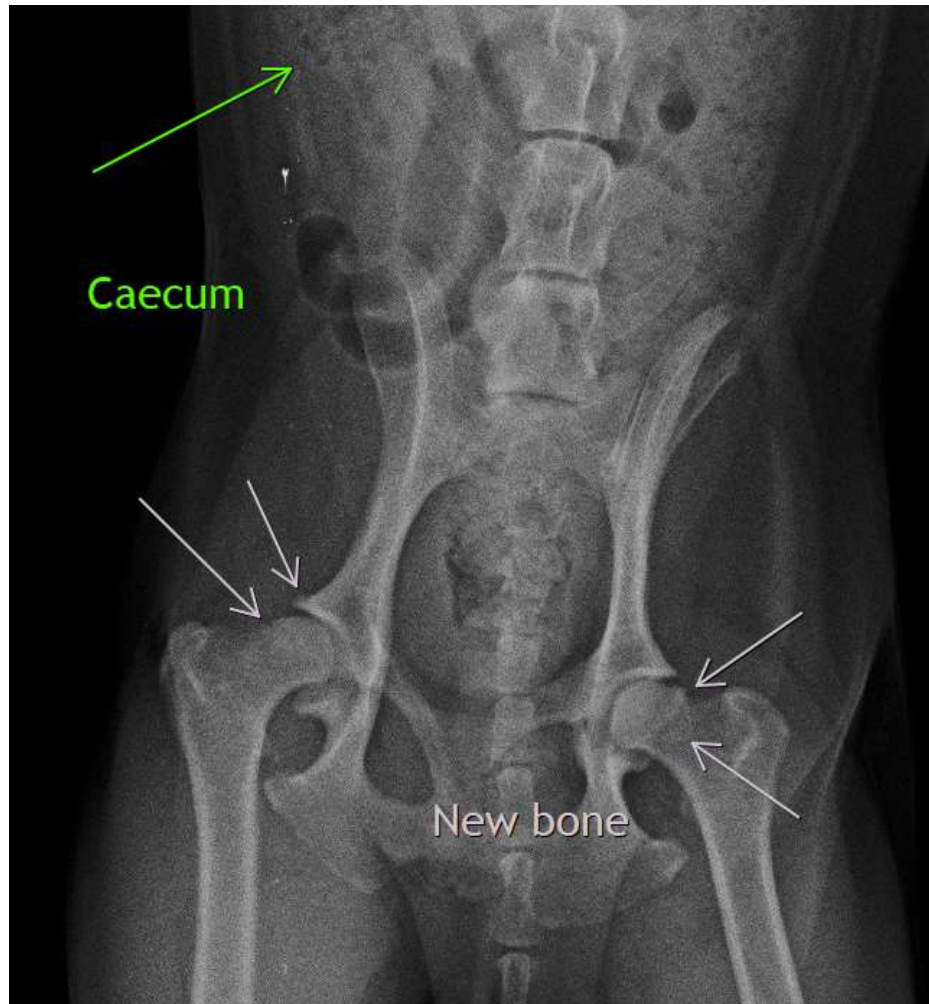
Katie Maher

INVOICE

50081

DATE

2-4-22



The information and recommendations provided are based on the images presented by the referring veterinarian/sonographer. No evaluation can be communicated regarding pathology that was not visible in the image/video clips provided.

Thank you for this referral. If the clinical or image interpretation does not parallel your findings or if I can be of any further assistance please contact me.

Heike Rudolf, DVM, Dr. med. vet., DipECVDDI, DVR
Dr.H.Rudorf@gmail.com