



PATIENT PRESENTING CLINICAL SIGNS

Shadow Thapa History: this dog came in with history of locked jaw, anorexia for 3 days, PE under sedation revealed a sewing needle with thread impeded in soft palate and tongue , it was removed easily . but radiographs showed a possibly another needle caudal to vocal box. exploratory surgery was performed yesterday to locate the needle in the esophagus unsuccessfully.
Abnormal PE/Chem/CBC/UA Results: unremarkable

SPECIES

Canine

RADIOGRAPHIC STUDY OF THE ABDOMEN AND NECK

BREED Abdomen

Shih Tzu Mix The body condition score is 5-6/9 with a tucked up abdominal wall.

SEX

Neutered Male

The bony structures are within normal limits.

The abdominal detail is in line with the body condition score; diaphragm and abdominal wall are intact.

The liver is located within the costal arch and the caudo-ventral lobe is pointed.

AGE

20 Months

The spleen appears physiological.

The stomach contains either air or Barium, depending on the date; distribution and size of the small intestinal loops appear physiological. Colon and rectum contain a moderate amount of fecal matter.

INTERPRETED BY

Heike Rudolf, DVM,
Dr. med. Vet.,
DipECVDI DVR

Both renal shadows are not clearly outlined. The bladder is located in the abdominal cavity and contains a small amount of homogeneous fluid opacity.

The sublumbar region appears physiological.

Neck

HOSPITAL NAME

St. Catharine's AH

The thyroid cartilage is well calcified. I can see no metal foreign object. After the administration of Barium the esophagus still contains a small amount of positive contrast medium which appears linear caudal to the thyroid cartilage. The retropharyngeal tissue appears physiological.

REFERRING VET

Dr. Boctor

RADIOGRAPHIC DIAGNOSIS

- Physiological studies

INVOICE

14092

INTERPRETATION OF THE FINDINGS & FURTHER RECOMMENDATIONS

I can see no metal object. The retained Barium in the cranial esophagus may be due to inflammation or could be due to small amount s of Barium being cleared from the mouth.

DATE

2/25/22

TECHNICAL COMMENTS



PATIENT

Human fingers in primary beam. Barium on dog's coat.

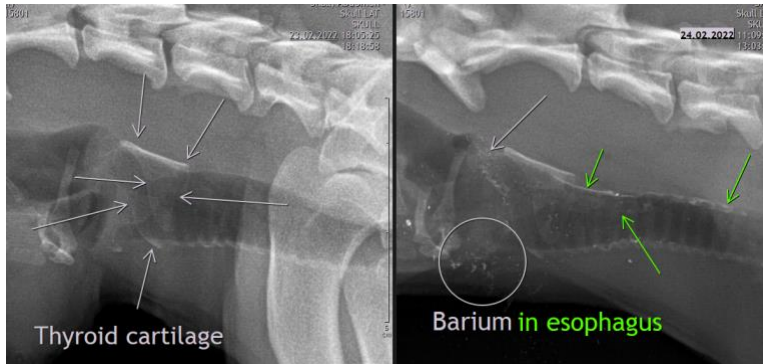
Shadow Thapa

SPECIES

Canine

BREED

Shih Tzu Mix



SEX

The information and recommendations provided are based on the images presented by the referring veterinarian/sonographer. No evaluation can be communicated regarding pathology that was not visible in the image/video clips provided.

Neutered Male

AGE

Thank you for this referral. If the clinical or image interpretation does not parallel your findings or if I can be of any further assistance please contact me.

20 Months

Heike Rudolf, DVM, Dr. med. vet., DipECVDI, DVR
dr.h.rudorf@gmail.com

INTERPRETED BY

Heike Rudolf, DVM,
Dr. med. Vet.,
DipECVDI DVR

HOSPITAL NAME

St. Catharine's AH

REFERRING VET

Dr. Boctor

INVOICE

14092

DATE

2/25/22