



PATIENT PRESENTING CLINICAL SIGNS

Ruby Ridge History: Was outside on ranch (cows are in process of giving birth so may have eaten something), came in uncontrollably shaking for about 25mins. When they go to lobby trembling stopped.

SPECIES Abnormal PE/Chem/CBC/UA Results: LARGE CENTRAL AREA OF FIRM FILL - ORGAN OR MASS OR FULL STOMACH/INTESTINE MILD DELAY IN REPLACING LEFT HIND WHEN TURNED OVER.
Canine DECREASED EXTENSION ROM OF RIGHT HIP.

RADIOGRAPHIC STUDY OF THE ABDOMEN

BREED

Black Mouth Cur Mix

The body condition score is 7/9 with a mild potbellied appearance.

Spondylosis is present ventral to T9/10 and L4-6.

SEX

The abdominal detail appears to be good.

Intact Female

The liver is located within the costal arch and the caudo-ventral lobe is pointed.

AGE

6 Years 4 Months

The spleen appears physiological.

The stomach contains a moderate amount of food. Distribution and size of the small intestinal loops appear physiological; the amount of gas in the intestinal lumen varies depending on the recumbency. The colon contains a small amount of formed of fecal matter.

INTERPRETED BY

Heike Rudolf, DVM,
 Dr. med. Vet.,
 DipECVDI DVR

Both renal shadows appear of physiological size, shape and opacity. The bladder is located in the abdominal cavity and contains a moderate amount of homogeneous fluid opacity.

The sublumbar region appears physiological.

HOSPITAL NAME

Elizabeth AH

RADIOGRAPHIC DIAGNOSIS

- Full stomach
- Slightly pendulous ventral abdominal wall
- Spondylosis

REFERRING VET

Dr. Leon Anderson

INTERPRETATION OF THE FINDINGS & FURTHER RECOMMENDATIONS

I can see no cause for the described clinical signs. To identify a gastric foreign body the radiograph will have to be repeated in the starved dog. This will also allow to identify if some or all intestinal loops have increased in size. Depending on other clinical signs present, Cushing's disease may have to be ruled out.

INVOICE

14093

The movement blur may be associated with pain elsewhere and mouth and neck should be inspected for perforation or foreign objects.

DATE

2/25/22

TECHNICAL COMMENTS



PATIENT

Movement blur on all lateral views

Ruby Ridge

SPECIES

Canine

BREED

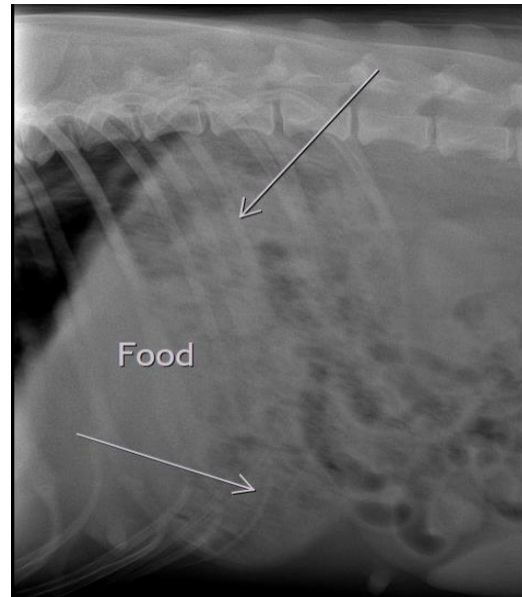
Black Mouth Cur Mix

SEX

Intact Female

AGE

6 Years 4 Months



The information and recommendations provided are based on the images presented by the referring veterinarian/sonographer. No evaluation can be communicated regarding pathology that was not visible in the image/video clips provided.

INTERPRETED BY

Heike Rudolf, DVM,
Dr. med. Vet.,
DipECVDI DVR

Thank you for this referral. If the clinical or image interpretation does not parallel your findings or if I can be of any further assistance please contact me.

Heike Rudolf, DVM, Dr. med. vet., DipECVDI, DVR
dr.h.rudorf@gmail.com

HOSPITAL NAME

Elizabeth AH

REFERRING VET

Dr. Leon Anderson

INVOICE

14093

DATE

2/25/22