



PATIENT PRESENTING CLINICAL SIGNS

Coco Graham History: Playing outside with the ball and after sprinting about 40 yards Coco suddenly sat down and didn't want to get up. When owner did get her up she was toe touching on hind left leg.

SPECIES Abnormal PE/Chem/CBC/UA Results: NON-WEIGHTBEARING LEFT HIND, PAINFUL TO EXTENSION
CRANIAL DRAWER LEFT HIND

Canine

RADIOGRAPHIC STUDY OF THE STIFLES

BREED The centre of the left femoral condyles is located slightly caudally to the intercondylar eminence.

Boxer Cranial fat pad and caudal fascial plains are almost completely obliterated by a soft tissue opacity within the joint. The tip of the patella is flat.

SEX

Spayed Female The centre of the right femoral condyles is in line with the intercondylar eminence. Cranial fat pad and caudal fascial plains are severely reduced by a soft tissue opacity within the joint. The tip of the patella shows new bone formation.

AGE

1 Year 5 Months

RADIOGRAPHIC DIAGNOSIS

- Left stifle: Cruciate ligament rupture
- Right stifle: Joint effusion and mild OA

INTERPRETED BY

Heike Rudorf, DVM,
Dr. med. Vet.,
DipECVDI DVR

INTERPRETATION OF THE FINDINGS & FURTHER RECOMMENDATIONS

The changes in the left stifle joint compliment the clinical findings and are compatible with an acute cruciate ligament rupture. The changes in the right stifle joint are more chronic (thus new bone on the patella) but an acute injury may be present as well and the soft tissue within the joint may represent fibrosis and effusion.

HOSPITAL NAME

Elizabeth AH

REFERRING VET

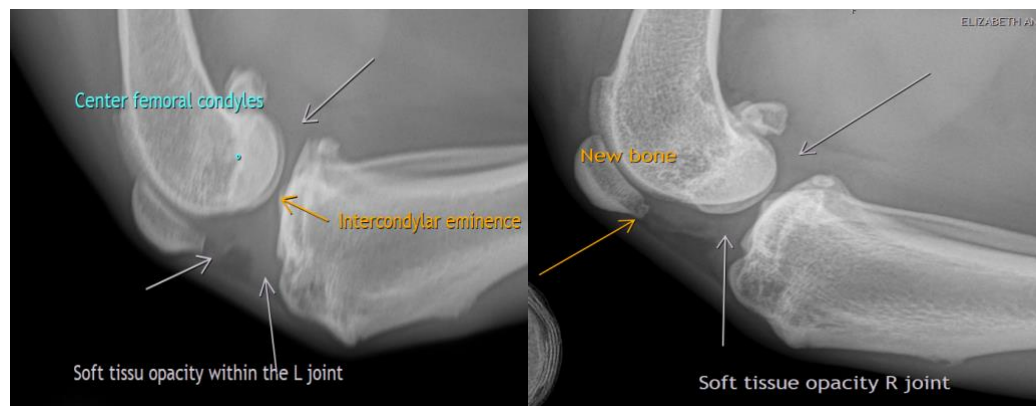
Kim Allyn, DVM

INVOICE

14090

DATE

2/25/22





PATIENT

Coco Graham

The information and recommendations provided are based on the images presented by the referring veterinarian/sonographer. No evaluation can be communicated regarding pathology that was not visible in the image/video clips provided.

SPECIES

Canine

Thank you for this referral. If the clinical or image interpretation does not parallel your findings or if I can be of any further assistance please contact me.

Heike Rudolf, DVM, Dr. med. vet., DipECVDI, DVR
dr.h.rudorf@gmail.com

BREED

Boxer

SEX

Spayed Female

AGE

1 Year 5 Months

INTERPRETED BY

Heike Rudolf, DVM,
Dr. med. Vet.,
DipECVDI DVR

HOSPITAL NAME

Elizabeth AH

REFERRING VET

Kim Allyn, DVM

INVOICE

14090

DATE

2/25/22