



PATIENT PRESENTING CLINICAL SIGNS

PATIENT Beacon Murphy **PRESENTING CLINICAL SIGNS** History: P Presented on 2/21 for generalized hind end pain. would shift weight from front to hind limbs. Painful on extension of hind limbs. Rectal exam was normal.

SPECIES RADIOGRAPHIC STUDY OF THE PELVIS AND L-SPINE

SPECIES Canine All bones are well mineralized, have a normal trabecular structure and a smooth surface. Cortical-medullary development and differentiation of the long bones are physiological.

BREED Pelvis

BREED Hound Mix The muscles of both hind limbs are symmetrical but poorly developed.

SEX

SEX Neutered Male The centre of both femoral heads is are superimposed onto their respective dorsal acetabular edge. One joint appears slightly wider than the other and a small amount of new bone formation is present on the femoral neck. Both hip joints appear congruent with even subchondral bone surfaces. No new bone formation is evident.

AGE

AGE 7 Years

L-Spine

The surrounding muscles and fat layers appear physiological.

No structural alterations are evident along the thoracic and lumbar spine. No signs of aggressive osteolysis have been identified. The disc spaces are of homogeneous width

INTERPRETED BY

Heike Rudolf, DVM,
Dr. med. Vet.,
DipECVDI DVR

RADIOGRAPHIC DIAGNOSIS

- Mild HD, bilateral
- Mild OA, unilateral

HOSPITAL NAME

Belvedere VC

INTERPRETATION OF THE FINDINGS & FURTHER RECOMMENDATIONS

The hip changes are mild and have been present for a while. Thus, it is unlikely that they are causing the recent onset of the described clinical signs they may, however, be contributing.

REFERRING VET

Elianne Amstalden

Accurate positioning of the spine is difficult even under G.A. and cord compression can only be identified with myelography or in cross sectional imaging. Cross sectional imaging is necessary to rule out disc disease, nerve root compression, neuritis and myositis.

INVOICE

14094

TECHNICAL COMMENTS

No side marker on VD pelvis

DATE

2/25/22



PATIENT

Beacon Murphy

SPECIES

Canine

BREED

Hound Mix

SEX

Neutered Male

AGE

7 Years

INTERPRETED BY

Heike Rudorf, DVM,
Dr. med. Vet.,
DipECVDI DVR

HOSPITAL NAME

Belvedere VC

REFERRING VET

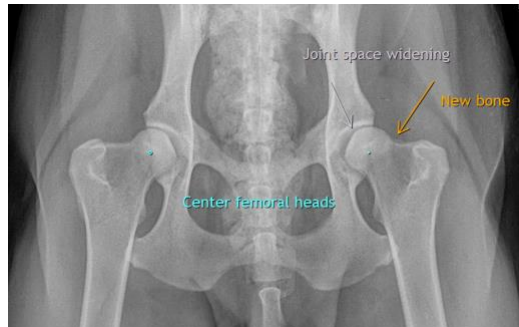
Elianne Amstalden

INVOICE

14094

DATE

2/25/22



The information and recommendations provided are based on the images presented by the referring veterinarian/sonographer. No evaluation can be communicated regarding pathology that was not visible in the image/video clips provided.

Thank you for this referral. If the clinical or image interpretation does not parallel your findings or if I can be of any further assistance please contact me.

Heike Rudorf, DVM, Dr. med. vet., DipECVDI, DVR
dr.h.rudorf@gmail.com