



PATIENT PRESENTING CLINICAL SIGNS

Annie Salerno History: P presents for possible URI. O states started yesterday. P is making a hacking noise like he is coughing. Not really eating. P is indoor, but goes outside when it is nice out. Chest sounds clear, purulent discharge from nose, severely dehydrated, halitosis, and drooling.

SPECIES RADIOGRAPHIC STUDY OF HEAD AND THORAX

Feline **Thorax**

The body condition score is 6/9 with smooth alternating layers of fat and soft tissue opacity.

BREED

The ribs appear straight on the lateral views.

DSH

A large gap is present between caudal heart border and dome of the diaphragm. The outline of the diaphragm on the VD shows the beginning of a “Christmas tree sign” on the left. The lungs are in contact with the thoracic boundaries and the tips are pointed. The outline of the tertiary lobar vessels is slightly smudged. The bronchial walls are thickened, tramlines and doughnuts are present. The left cranial lobar bronchus does not taper after the first branch.

SEX

Neutered Male

The cranial mediastinum is of physiological size and opacity. Air is present in the cranial thoracic esophagus on the left lateral recumbent view. The trachea diverges from the thoracic vertebrae and dips at the carina.

AGE

7 Years

The cardiac silhouette occupies 75% of the chest height and 2 intercostal spaces. No chamber or outflow tract enlargement is evident.

INTERPRETED BY

A large amount of air is distending the stomach. Gas is present in the entire intestine.

Heike Rudorf, DVM,
Dr. med. Vet.,
DipECVDI DVR

Head

The maxillary incisor teeth are missing.

The right nostril contains less air than the left.

HOSPITAL NAME

The Pet Hospital of
Stratford

The visible part of the nasal chambers is air filled and turbinates are present. The other structures also appear physiological.

RADIOGRAPHIC DIAGNOSIS

REFERRING VET

Dr. Claudia Guiliani,
DVM

- Peribronchial infiltrate
- Bronchiectasis
- Pulmonary overexpansion
- Aerophagia
- Partially occluded right nostril

Incidental findings

INVOICE

21283

- Spondylosis
- Missing teeth

DATE

2/24/23



PATIENT INTERPRETATION OF THE FINDINGS & FURTHER RECOMMENDATIONS

Annie Salerno

SPECIES

Feline

BREED

DSH

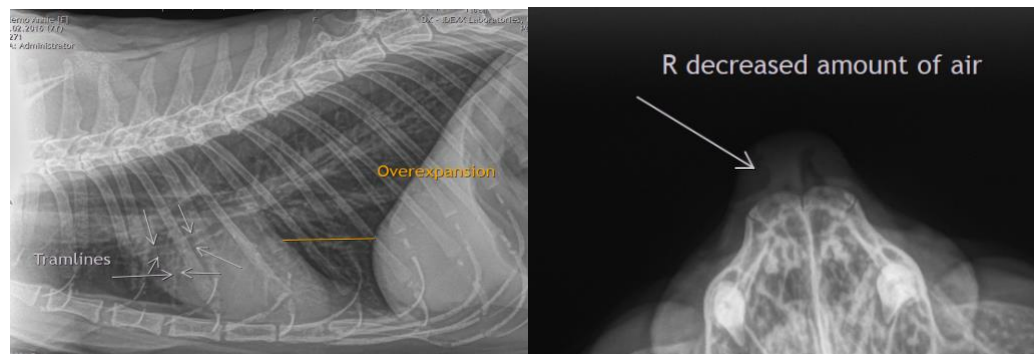
SEX

Neutered Male

AGE

7 Years

The thoracic changes are compatible with bronchitis, which can be infectious or inflammatory. In combination with the overexpansion of the lungs and the bronchiectasis, feline asthma is likely. Partial obstruction of the nostril can be due to fluid accumulation (e.g. pus, blood) or tumour (squamous cell carcinoma). Tracheobronchoscopy and broncho-alveolar lavage should be obtained for histology and bacteriology. Visual inspection of the nares and /or rhinoscopy is recommended to rule out a tumour of the rostral nasal septum. In case rhinoscopy is not possible, CT can help identify turbinate pathology. A sample of the nasal discharge should also be sent to bacteriology. Drooling can be due to an inability to swallow or could be the result of pain. Inspection of pharynx, larynx and tonsils is recommended. The treatment of coexisting dental disease may also help.



The information and recommendations provided are based on the images presented by the referring veterinarian/sonographer. No evaluation can be communicated regarding pathology that was not visible in the image/video clips provided.

INTERPRETED BY

Heike Rudolf, DVM,
Dr. med. Vet.,
DipECVDI DVR

Thank you for this referral. If the clinical or image interpretation does not parallel your findings or if I can be of any further assistance please contact me.

HOSPITAL NAME

The Pet Hospital of
Stratford

Heike Rudolf, DVM, Dr. med. vet., DipECVDI, DVR
dr.h.rudorf@gmail.com

REFERRING VET

Dr. Claudia Guiliani,
DVM

INVOICE

21283

DATE

2/24/23