



PATIENT PRESENTING CLINICAL SIGNS

PATIENT Rocky Williams
HISTORY: Presented yesterday for shortness of breath. Crackles were auscultated bilaterally. He has a history of Grade III/VI LAS murmur as well as tracheal collapse. Owner reported that Rocky improved after rads performed Tuesday and started on pimobendan and Lasix. Today, they report no improvement

SPECIES

SPECIES Canine
RESULTS: Abnormal PE/Chem/CBC/UA Results: Crackles auscultated bilaterally Limited Echo submitted to sonopath HR - 130 T - 101.5 BCS 8/9 Grade III/VI LAS murmur BP 118/106 98% SPO2

BREED RADIOGRAPHIC STUDY OF THE THORAX

BREED Shih Tzu
 The body condition score is 7/9 with smooth alternating layers of fat and soft tissue opacity.

SEX

SEX Neutered Male
 A mild lordosis is present between T6 and T11. Rib 13 on the right is underdeveloped.
 The degree of pulmonary expansion is fair at best on all views. The lungs are in contact with the thoracic boundaries and the tips are pointed. The main lobar vessels are visible and there is an impression of a linear, reticular pattern.

AGE

AGE 12 Years
 The cranial mediastinum is of physiological size and opacity. The trachea slightly diverges from the thoracic vertebrae and the carina is located at T5.

INTERPRETED BY

INTERPRETED BY Heike Rudolf, DVM, Dr. med. Vet., DipECVDI DVR
 The cardiac silhouette occupies 80% of the chest height and 3.5 intercostal spaces (VHS 10). The caudal heart border appears slightly straight, and the two main stem bronchi appear pushed apart slightly but each one is straight.

Both studies show a large gall bladder calculus.

RADIOGRAPHIC DIAGNOSIS

HOSPITAL NAME

HOSPITAL NAME Torch Lakes VC

- Reduced lung expansion
- Reticular interstitial pattern

Incidental Findings

REFERRING VET

REFERRING VET A. Waffle

- Gall bladder calculus
- Congenital spinal and rib anomalies

INVOICE

INVOICE 14059
INTERPRETATION OF THE FINDINGS & FURTHER RECOMMENDATIONS
 A generalized interstitial lung pattern is a non-specific finding and accentuated by the only fair expansion of the lung field. Possible differential diagnoses for a true infiltrate include:

DATE

DATE 2/24/22

- Fibrosis



PATIENT

Rocky Williams

- Inflammation (allergic e.g. eosinophilic bronchopneumonia and PIE, smoke inhalation)
- Infection (bacterial, fungal e.g. candida, viral, Rickettsia, Spirochetes, parasitic)
- Edema
- Hemorrhage
- Tumor (e.g. lymphoma)

SPECIES

Canine

The combination of clinical signs, poor lung expansion on all views, and interstitial pattern, lung fibrosis seems to be the most likely cause for the shortness of breath. Obesity is known to worsen clinical signs of cough and impair lung function; weight control is strongly recommended.

BREED

Shih Tzu

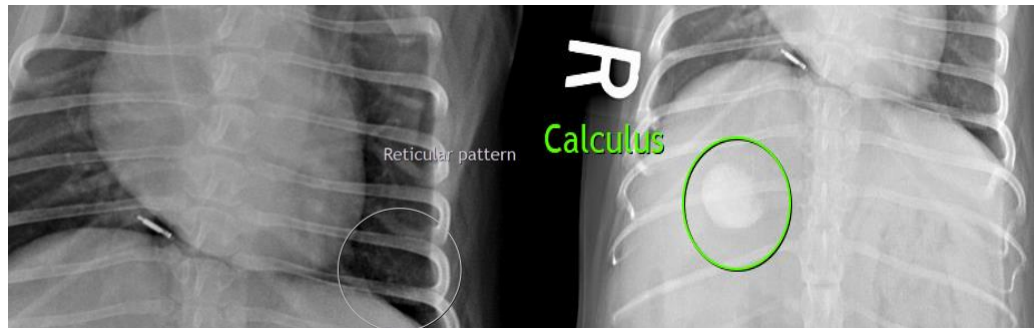
Tracheal collapse alone can be due to a weakened dorsal tracheal ligament. Tracheal in combination with bronchial collapse is usually caused by chondromalacia and is thus due to an altered cartilage development. Both may go unnoticed until physical circumstances (such as stress, running, excitement) or disease (e.g., pneumonia, bronchitis, left cardiac enlargement) reduces the ease of airflow. Echocardiography to assess mitral valve and left atrial size has already been performed and bronchoscopy to obtain a BAL is recommended to rule out an additional, e.g. inflammatory, infiltrate. However, this depends on the clinical presentation of the patient because the time after extubation can be difficult for animals with fibrosis and tracheal collapse.

SEX

Neutered Male

AGE

12 Years



INTERPRETED BY

Heike Rudolf, DVM,
Dr. med. Vet.,
DipECVDI DVR

HOSPITAL NAME

Torch Lakes VC

The information and recommendations provided are based on the images presented by the referring veterinarian/sonographer. No evaluation can be communicated regarding pathology that was not visible in the image/video clips provided.

Thank you for this referral. If the clinical or image interpretation does not parallel your findings or if I can be of any further assistance please contact me.

REFERRING VET

A. Waffle

Heike Rudolf, DVM, Dr. med. vet., DipECVDI, DVR
dr.h.rudorf@gmail.com

INVOICE

14059

DATE

2/24/22



PATIENT

Rocky Williams

SPECIES

Canine

BREED

Shih Tzu

SEX

Neutered Male

AGE

12 Years

INTERPRETED BY

Heike Rudolf, DVM,
Dr. med. Vet.,
DipECVDI DVR

HOSPITAL NAME

Torch Lakes VC

REFERRING VET

A. Waffle

INVOICE

14059

DATE

2/24/22