



**PATIENT PRESENTING CLINICAL SIGNS**

Holly Grant History: Rescued 10/21, recurrent g.i. issues, chronic gagging after drinking, panting. Symptoms are pred responsive. ACTH stim post 7.9(WNL).

**SPECIES RADIOGRAPHIC STUDY OF THE THORAX**

Canine The body condition score is 5/9.

The bony structures appear physiological.

**BREED**

Mixed Breed The lungs are in contact with the thoracic boundaries and the tips are pointed. On the VD view the left caudal lobe shows a loss of clear vascular outline and highlighting of bronchi. The other lobar vessels are clearly visible to the tertiary branches. The bronchial tree is thin walled and tapers uniformly towards the periphery.

**SEX**

Female The cranial mediastinum is of physiological size and opacity. The trachea diverges from the thoracic vertebrae and the carina is located at T5.

**AGE**

2 Years The cardiac silhouette occupies 75% of the chest height and 2.5 intercostal spaces. No chamber or outflow tract enlargement is evident.

**RADIOGRAPHIC DIAGNOSIS**

- Interstitial pattern left caudal lobe

**INTERPRETED BY**

Heike Rudolf, DVM,  
Dr. med. Vet.,  
DipECVDI DVR

**INTERPRETATION OF THE FINDINGS & FURTHER RECOMMENDATIONS**

The interstitial lung pattern is a non-specific finding and could be the result of a left lateral recumbency prior to the taking the VD. Possible differential diagnoses for a true infiltrate include:

**HOSPITAL NAME**

Veterinary Care  
Center (Mercerville,  
NJ)

- Infection (bacterial, fungal e.g., candida, viral, Rickettsia, Spirochetes, parasitic)
- Inflammation (allergic e.g., eosinophilic bronchopneumonia and PIE, smoke inhalation)
- Edema
- Hemorrhage

Considering the long history of the clinical signs, further examinations should be considered. To rule out tonsillar enlargement and laryngeal disease such as paralysis, edema and viral inflammation, visual inspection s necessary. This can be followed by tracheobronchoscopy with bronchoalveolar lavage because bronchitis can be present without radiographic evidence. Corticosteroids have to be withheld for at least 7 days prior to the examination.

**REFERRING VET**

Dr. Horn

**INVOICE**

14065

**DATE**

2/24/22



**PATIENT**

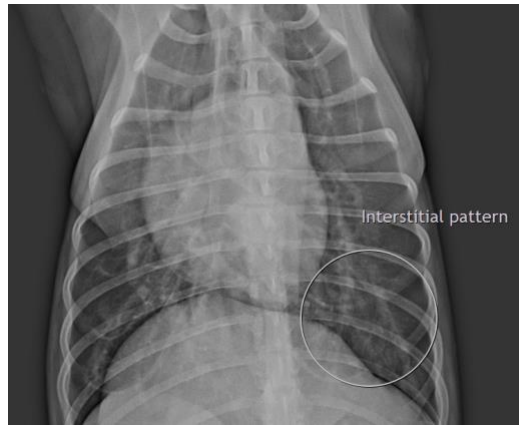
Holly Grant

**SPECIES**

Canine

**BREED**

Mixed Breed



**SEX**

Female

**AGE**

2 Years

**The information and recommendations provided are based on the images presented by the referring veterinarian/sonographer. No evaluation can be communicated regarding pathology that was not visible in the image/video clips provided.**

Thank you for this referral. If the clinical or image interpretation does not parallel your findings or if I can be of any further assistance please contact me.

**Heike Rudorf**, DVM, Dr. med. vet., DipECVDI, DVR  
dr.h.rudorf@gmail.com

**INTERPRETED BY**

Heike Rudorf, DVM,  
Dr. med. Vet.,  
DipECVDI DVR

**HOSPITAL NAME**

Veterinary Care  
Center (Mercerville,  
NJ)

**REFERRING VET**

Dr. Horn

**INVOICE**

14065

**DATE**

2/24/22