



**PATIENT PRESENTING CLINICAL SIGNS**

Annabell MacDonald History: Second nipple oozing, x-ray sent for possible metastatic tumor on left side  
Abnormal PE/Chem/CBC/UA Results: mild elevated ALT and BUN

**SPECIES RADIOGRAPHIC STUDY OF THE THORAX**

Feline The body condition score is 7/9 with a large amount of subcutaneous fat lateral to the rib cage. A large, soft tissue mass, associated with a nipple, is located on the left ventral skin surface.

**BREED** The bony structures appear physiological.

DSH The lungs are in contact with the thoracic boundaries and the tips are pointed; the distance between caudal heart border and dome of the diaphragm is increased. The lobar vessels are clearly visible to the tertiary branches. The bronchial tree is thin walled and tapers uniformly towards the periphery.

**SEX**

Spayed Female The cranial mediastinum is of physiological size and opacity. The trachea diverges from the thoracic vertebrae and the carina is located at T5.

**AGE**

7 Years

The cardiac silhouette occupies 75% of the chest height and 2 intercostal spaces. No chamber or outflow tract enlargement is evident.

**RADIOGRAPHIC DIAGNOSIS**

- Soft tissue mass in region of cranial, left mammary gland

**INTERPRETED BY**

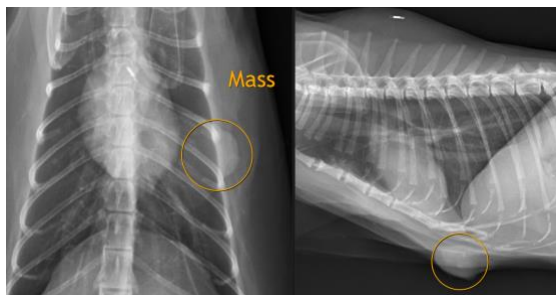
Heike Rudorf, DVM,  
Dr. med. Vet.,  
DipECVDI DVR

**INTERPRETATION OF THE FINDINGS & FURTHER RECOMMENDATIONS**

I can see no lung metastases or lymph node enlargement.

**HOSPITAL NAME**

St. Catharine's AH



**REFERRING VET**

Dr. Masoud

**INVOICE**

14064

**The information and recommendations provided are based on the images presented by the referring veterinarian/sonographer. No evaluation can be communicated regarding pathology that was not visible in the image/video clips provided.**

**DATE**

2/24/22

Thank you for this referral. If the clinical or image interpretation does not parallel your findings or if I can be of any further assistance please contact me.



**PATIENT**

Annabell MacDonald

**Heike Rudolf**, DVM, Dr. med. vet., DipECVDI, DVR  
[dr.h.rudorf@gmail.com](mailto:dr.h.rudorf@gmail.com)

**SPECIES**

Feline

**BREED**

DSH

**SEX**

Spayed Female

**AGE**

7 Years

**INTERPRETED BY**

Heike Rudolf, DVM,  
Dr. med. Vet.,  
DipECVDI DVR

**HOSPITAL NAME**

St. Catharine's AH

**REFERRING VET**

Dr. Masoud

**INVOICE**

14064

**DATE**

2/24/22