



PATIENT PRESENTING CLINICAL SIGNS

Cocoa Dezso History: Pt presented for follow-up from ER 2.5days ago. Pt presented there for blood in urine and shaking. Ua/c&s was done and pt was put on clavamox. O reports pt not doing much better. Pt not eating well, not herself. Pt vomited up clavamox this AM, but otherwise no vomit. Smaller amount of stools, because pt not eating well, but normal consistency. Pt still shaking. O has video showing some trembling. O also said she saw a worm in her urine. BW and ua/c&s pending.

SPECIES

Canine **RADIOGRAPHIC STUDY OF THE ABDOMEN**

BREED The body condition score is 7-8/9 with a large amount of subcutaneous fat dorsal to the lumbar spine.

The bony structures are within normal limits.

Puggle

The abdominal detail is good, a large amount of sublumbar fat is present. Diaphragm and abdominal wall are intact.

SEX

Spayed Female The liver is located within the costal arch.

A splenic shadow is not obvious.

AGE

6 Years The stomach contains a small amount of air; distribution and size of the small intestinal loops appear physiological. Colon and rectum contain a moderate amount of fecal matter.

The left renal shadow has a physiological size, shape and opacity, the right is obscured by intestinal loops. The bladder is located in the abdominal cavity, is rounded and contains a small amount of homogeneous fluid opacity.

INTERPRETED BY

Heike Rudolf, DVM, Dr. med. Vet., DipECVDI DVR The region of the uterine body appears physiological.

The sublumbar region appears physiological.

HOSPITAL NAME

RADIOGRAPHIC DIAGNOSIS

The Pet Hospital of Stratford

- Rounded bladder shadow

INTERPRETATION OF THE FINDINGS & FURTHER RECOMMENDATIONS

REFERRING VET

Dr. David I can see no causes for the clinical signs. Possible causes for blood on the vulva could be renal disease, cystitis, bladder neck tumor, uterine stump and vaginal pathology. Abdominal ultrasound with cystocentesis is recommended. Urinary examination should include bacteriology and cytology. Causes for shaking include pain (visceral or spinal). Thus, full biochemistry and hematology should be carried out if it has not already been done.

INVOICE

21273

DATE

2/23/23



PATIENT

Cocoa Dezzo

SPECIES

Canine

BREED

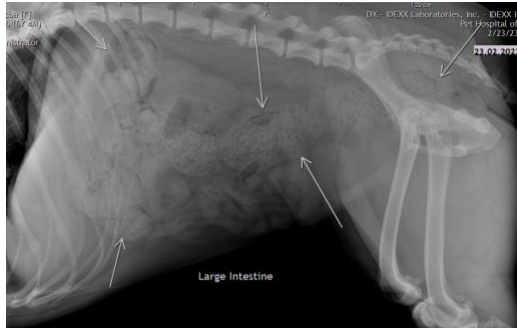
Puggle

SEX

Spayed Female

AGE

6 Years



The information and recommendations provided are based on the images presented by the referring veterinarian/sonographer. No evaluation can be communicated regarding pathology that was not visible in the image/video clips provided.

Thank you for this referral. If the clinical or image interpretation does not parallel your findings or if I can be of any further assistance please contact me.

Heike Rudorf, DVM, Dr. med. vet., DipECVDI, DVR
dr.h.rudorf@gmail.com

INTERPRETED BY

Heike Rudorf, DVM,
Dr. med. Vet.,
DipECVDI DVR

HOSPITAL NAME

The Pet Hospital of
Stratford

REFERRING VET

Dr. David

INVOICE

21273

DATE

2/23/23