



PATIENT PRESENTING CLINICAL SIGNS

Bella Davis History: Bella has been repeatedly constipated and has required Enemas multiple times. Lactulose and Miralax are not helping. Bella threw up yesterday and this morning.

SPECIES Abnormal PE/Chem/CBC/UA Results: Steady but slow weight loss. Abdomen seems more full. No stool felt in colon. Remainder appears normal.

Feline **RADIOGRAPHIC STUDY OF THE ABDOMEN**

BREED Thin wires are located in the ventral abdominal wall.

American Shorthair L7 is a transitional vertebra. Ventral spondylosis is present on L5-7. The size of the pelvic canal is physiological.

SEX The abdominal detail is good; diaphragm and abdominal wall are intact.

Spayed Female The liver is located within the costal arch and the caudo-ventral lobe is superimposed by a large ascending colon.

AGE The spleen appears prominent on one VD view.

12 Years 6 Months The fundus of the stomach contains a small amount of gas with mineral opacities as well as some fluid. Distribution and size of the small intestinal loops appear physiological. The diameter of all colonic segments is increased. Unformed feces are located in ascending and transvers colon. The descending colon is distended with gas. Gas and fluid appears to be located in the rectum.

INTERPRETED BY

Heike Rudolf, DVM, Dr. med. Vet., DipECVDI DVR Both renal shadows have a physiological size, shape and opacity. The bladder is located in the abdominal cavity and contains a small amount of homogeneous fluid opacity.

The sublumbar region appears physiological.

HOSPITAL NAME

Elizabeth AH

RADIOGRAPHIC DIAGNOSIS

- Megacolon

Incidental findings

REFERRING VET

- Transitional vertebra
- Spondylosis
- Wire sutures abdominal wall

Leon Anderson, DVM

INVOICE

21274

INTERPRETATION OF THE FINDINGS & FURTHER RECOMMENDATIONS

I can see no anatomical causes for the megacolon; the transitional vertebra is unlikely to be relevant. Once ultrasound of the colonic and rectal walls or colonoscopy have ruled out tumor and chronic inflammation, idiopathic megacolon is the most likely diagnosis. This is usually caused by a neuropathy of the colonic ganglia. The entire colon appears to be affected; thus a subtotal colectomy is unlikely to solve the problem.

DATE

2/23/23



PATIENT

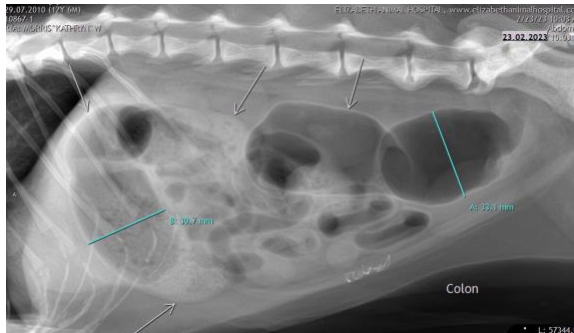
Bella Davis

SPECIES

Feline

BREED

American Shorthair



The information and recommendations provided are based on the images presented by the referring veterinarian/sonographer. No evaluation can be communicated regarding pathology that was not visible in the image/video clips provided.

SEX

Spayed Female

Thank you for this referral. If the clinical or image interpretation does not parallel your findings or if I can be of any further assistance please contact me.

AGE

12 Years 6 Months

Heike Rudolf, DVM, Dr. med. vet., DipECVDI, DVR
dr.h.rudorf@gmail.com

INTERPRETED BY

Heike Rudolf, DVM,
Dr. med. Vet.,
DipECVDI DVR

HOSPITAL NAME

Elizabeth AH

REFERRING VET

Leon Anderson, DVM

INVOICE

21274

DATE

2/23/23