



**PATIENT PRESENTING CLINICAL SIGNS**

Cleopatra Werner History: 2 weeks left FL lameness - pain on extension of left elbow consistently.  
 Abnormal PE/Chem/CBC/UA Results: Incidental finding of lymphocytosis on BW. FeLV/FIV negative.

**SPECIES RADIOGRAPHIC STUDY OF THE ELBOWS**

Feline The skin surfaces are smooth, and the muscles appear to be symmetrically developed.  
 The bones are well mineralized, have a normal trabecular structure and smooth, continuous surfaces.  
**BREED** Cortical-medullary development and differentiation of the long bones are physiological.

DLH The elbow joints are congruent with smooth subchondral bone surfaces. On both cranio-caudal views bone as well as joint surfaces are smooth.

**SEX INTERPRETATION OF THE FINDINGS & FURTHER RECOMMENDATIONS**

Spayed Female I can see no changes that would explain the clinical signs. A cat bite abscess cannot be ruled. Pain will, however, be present long before obvious alterations of size and shape of the soft tissues develop. Close observation is recommended. Further imaging of soft tissue structures may become necessary and an initial ultrasound of a painful region may suffice. Otherwise, cross sectional imaging will be necessary.

**AGE**

9

**TECHNICAL COMMENTS**

No side marker on cranio-caudal views.

**INTERPRETED BY**

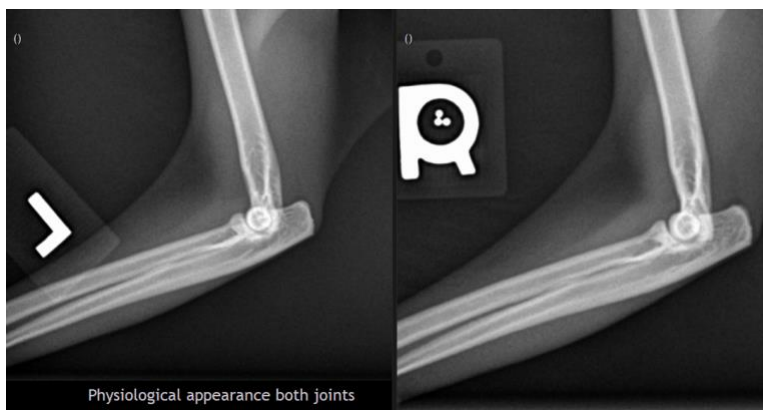
Heike Rudorf, DVM,  
 Dr. med. Vet.,  
 DipECVDI DVR

**HOSPITAL NAME**

Incline VH

**REFERRING VET**

Dr. Mulchi



**INVOICE**

21271

**The information and recommendations provided are based on the images presented by the referring veterinarian/sonographer. No evaluation can be communicated regarding pathology that was not visible in the image/video clips provided.**

Thank you for this referral. If the clinical or image interpretation does not parallel your findings or if I can be of any further assistance please contact me.

**DATE**

2/21/23



**PATIENT**

**Heike Rudolf**, DVM, Dr. med. vet., DipECVDI, DVR  
dr.h.rudorf@gmail.com

Cleopatra Werner

**SPECIES**

Feline

**BREED**

DLH

**SEX**

Spayed Female

**AGE**

9

**INTERPRETED BY**

Heike Rudolf, DVM,  
Dr. med. Vet.,  
DipECVDI DVR

**HOSPITAL NAME**

Incline VH

**REFERRING VET**

Dr. Mulchi

**INVOICE**

21271

**DATE**

2/21/23