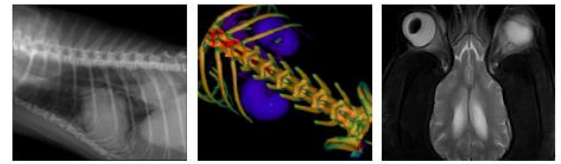


PATIENT	PRESENTING CLINICAL SIGNS
"Stewie" Arnone	Intermittent non weight bearing lameness LH. Progressively worse. Abnormal PE/Chem/CBC/UA Results: Cranial drawer present bilaterally.
SPECIES	RADIOGRAPH OF PELVIS AND STIFLES
Canine	1x VD pelvis including stifles in frog leg, R and L lateral stifle
BREED	RADIOGRAPHIC FINDINGS
Yorkshire Terrier	All bones are well mineralized, have a normal trabecular structure and a smooth surface. Cortical-medullary development and differentiation of the long bones are physiological.
SEX	<u>Pelvis</u>
MN	Both femoral heads appear thick and new bone appears to be present along both femoral necks. On the R new bone is also present on the cranial and caudal acetabular edges.
AGE	<u>Stifles</u>
13 Years	Both stifle joints have smooth subchondral bone surfaces. The centre of the R femoral condyle appears to be located caudal to the intercondylar eminence. The cranial fat pad is reduced, and the caudal fascial plains are caudally displaced more on the L than on the R. New bone formation is present on fabellae, femoral ridges and tibial plateau. The L patella is superimposed over the condyles; the R patella is partially superimposed onto the condyles
INTERPRETED BY	RADIOGRAPHIC DIAGNOSIS
Heike Rudolf, DVM, Dr. med. Vet., DipECVDI DVR	<ul style="list-style-type: none">• Patella luxation L more than R• Cruciate lig. rupture L• Stifle effusion L more than R• Stifle OA, bilateral• Bilateral hip joint OA
HOSPITAL NAME	INTERPRETATION OF THE FINDINGS & FURTHER RECOMMENDATIONS
Pinebrook Animal Hospital	The patella luxation has probably been present the dog's entire life. Arthritic changes are present in both stifle joints indicating chronic, low grade instability. The images suggest a left sided cruciate ligament rupture which most likely is the reason for the current, severe L sided lameness. Surgery is recommended.
REFERRING VET	
Dr. Britt Dubil	
INVOICE	
50380	
DATE	
2-18-22	



PATIENT

"Stewie" Arnone

SPECIES

Canine

BREED

Yorkshire Terrier

SEX

MN

AGE

13 Years

INTERPRETED BY

Heike Rudolf, DVM,
Dr. med. Vet.,
DipECVDI DVR

HOSPITAL NAME

Pinebrook Animal
Hospital

REFERRING VET

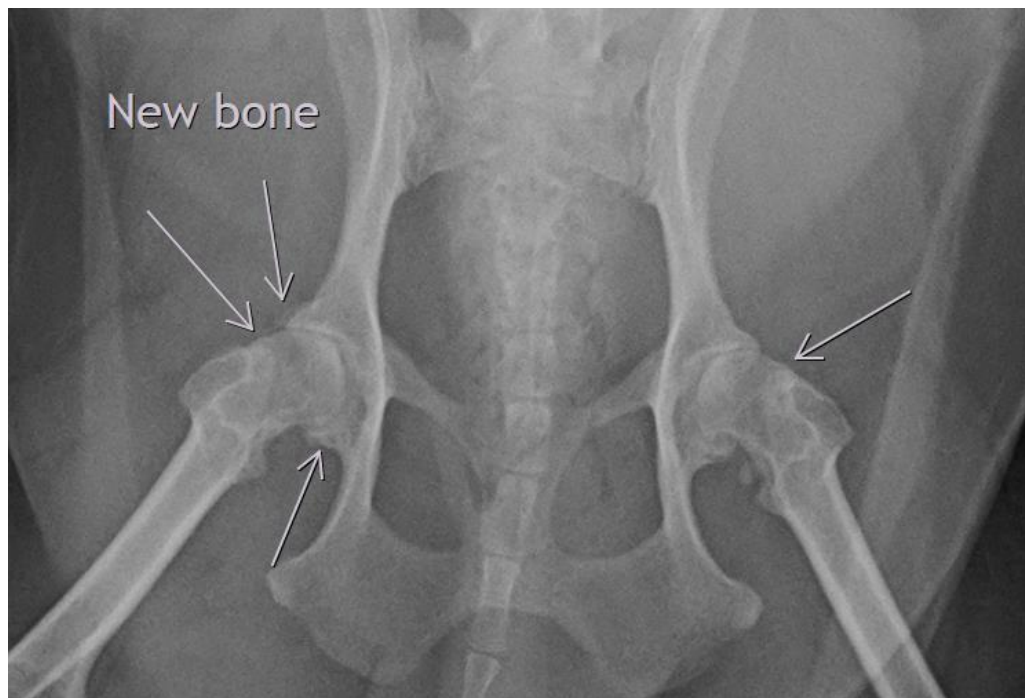
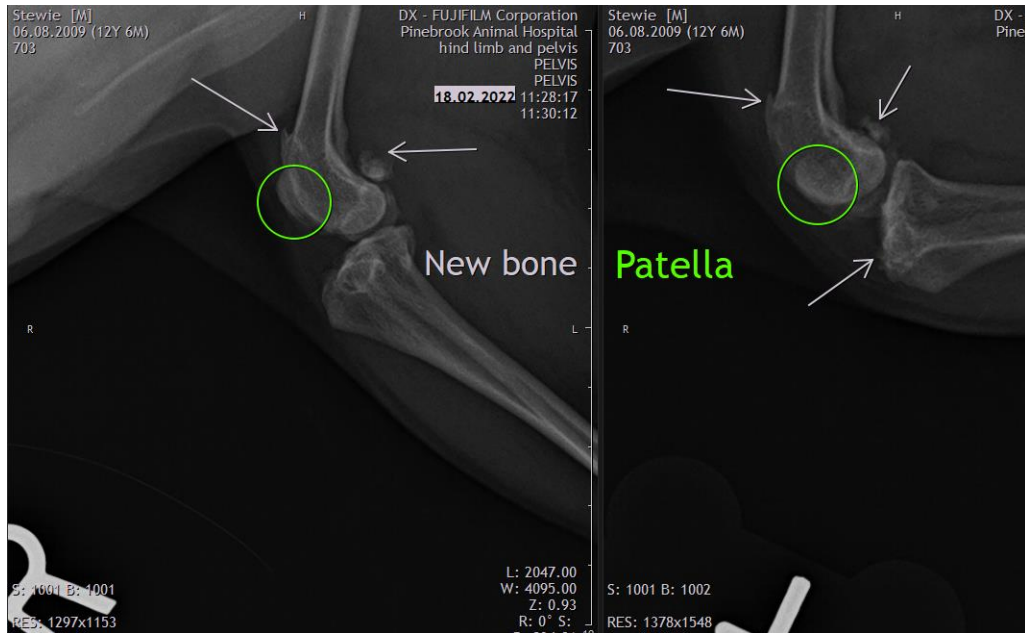
Dr. Britt Dubil

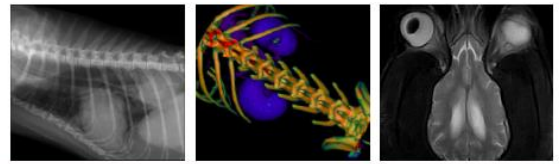
INVOICE

50380

DATE

2-18-22





PATIENT

"Stewie" Arnone

The information and recommendations provided are based on the images presented by the referring veterinarian/sonographer. No evaluation can be communicated regarding pathology that was not visible in the image/video clips provided.

SPECIES

Canine

Thank you for this referral. If the clinical or image interpretation does not parallel your findings or if I can be of any further assistance please contact me.

BREED

Yorkshire Terrier

Heike Rudorf, DVM, Dr. med. vet., DipECVDI, DVR
Dr.H.Rudorf@gmail.com

SEX

MN

AGE

13 Years

INTERPRETED BY

Heike Rudorf, DVM,
Dr. med. Vet.,
DipECVDI DVR

HOSPITAL NAME

Pinebrook Animal
Hospital

REFERRING VET

Dr. Britt Dubil

INVOICE

50380

DATE

2-18-22