



PATIENT PRESENTING CLINICAL SIGNS

Savannah Cardone History: Chronic coughing at nighttime

RADIOGRAPHIC STUDY OF THE THORAX AND NECK

SPECIES The body condition score is 7/9 with smooth alternating layers of fat and soft tissue opacity.

Canine The bony structures appear physiological.

BREED The degree of pulmonary expansion is fair. The lungs are in contact with the thoracic boundaries and the tips are pointed. The lobar vessels are visible to the secondary branches. The bronchial tree is thin walled and tapers towards the periphery.

Mixed The cranial mediastinum is of physiological size and opacity. The trachea diverges from the thoracic vertebrae and the carina is located at T5.

SEX The cardiac silhouette occupies 75% of the chest height and 3 intercostal spaces. No chamber or outflow tract enlargement is evident.

Spayed Female

RADIOGRAPHIC DIAGNOSIS

AGE • Interstitial pattern

12 Years **INTERPRETATION OF THE FINDINGS & FURTHER RECOMMENDATIONS**

The generalized interstitial lung pattern is a non-specific finding and accentuated by the only fair expansion of the lung field. Possible differential diagnoses for a true infiltrate include:

INTERPRETED BY

Heike Rudolf, DVM,
Dr. med. Vet.,
DipECVDI DVR

- Infection (bacterial, fungal e.g. candida, viral, Rickettsia, Spirochetes, parasitic)
- Inflammation (allergic e.g. eosinophilic bronchopneumonia and PIE, smoke inhalation)
- Edema
- Hemorrhage
- Fibrosis
- Tumor (e.g. lymphoma)

HOSPITAL NAME

New Bridge VP

Echocardiography and trachea-bronchoscopy with BAL will help rule out cardiac and pulmonary origins. Trachea and bronchi should be assessed for collapse; pharynx and larynx inspected for abnormalities (e.g. tonsillar mass). Obesity is known to worsen clinical signs of cough and impair lung function; weight control is strongly recommended.

REFERRING VET

Dr. Abina Glennon

INVOICE

21176

DATE

2/17/23



PATIENT

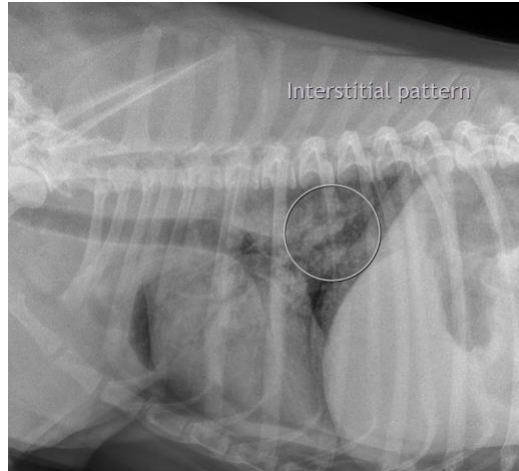
Savannah Cardone

SPECIES

Canine

BREED

Mixed



SEX

Spayed Female

The information and recommendations provided are based on the images presented by the referring veterinarian/sonographer. No evaluation can be communicated regarding pathology that was not visible in the image/video clips provided.

AGE

12 Years

Thank you for this referral. If the clinical or image interpretation does not parallel your findings or if I can be of any further assistance please contact me.

Heike Rudorf, DVM, Dr. med. vet., DipECVDI, DVR
dr.h.rudorf@gmail.com

INTERPRETED BY

Heike Rudorf, DVM,
Dr. med. Vet.,
DipECVDI DVR

HOSPITAL NAME

New Bridge VP

REFERRING VET

Dr. Abina Glennon

INVOICE

21176

DATE

2/17/23