



PATIENT PRESENTING CLINICAL SIGNS

Bubby Teplyakova
 History: Rechecking: Diarrhea history: o states diarrhea never really resolved even on meds. yesterday lethargy not eating. o got p to eat canned pumpkin which helped the stool but still diarrhea. no blood in stool but mucous. o reports flatulence and borborygmus. also, o noticed bump on r hind hip area first noticed few days ago has gotten smaller. no vomit

SPECIES

Canine
 Abnormal PE/Chem/CBC/UA Results: Exam Notes: BAR slightly dehydrated slightly tense on abdominal palpation r/o FB, enteritis, pancreatitis, intestinal parasites, other

BREED RADIOGRAPHIC STUDY OF THE ABDOMEN

Chihuahua
 The body condition score is 6/9 with a large amount of caudo-dorsal subcutaneous fat.

The bony structures are within normal limits.

SEX

Neutered Male
 The abdominal detail is good; diaphragm and abdominal wall are intact.

The liver is located well within the costal arch and the caudo-ventral lobe is pointed.

AGE

6 Years 4 Months
 The head of the spleen appears physiological, the tail is not visible ventrally.
 The stomach contains a moderate amount of solid food; distribution and size of the small intestinal loops appear physiological; they mostly contain gas. Colon and rectum contain a moderate amount of fecal matter.

INTERPRETED BY

Heike Rudolf, DVM, Dr. med. Vet., DipECVDI DVR
 The left renal shadow has a physiological size, shape and opacity; the right is obscured by intestinal loops. The bladder is located in the abdominal cavity and contains a small amount of homogeneous fluid opacity.

The prostate gland is small.

HOSPITAL NAME

DPC Veterinary Hospital
 The sublumbar region appears physiological.

RADIOGRAPHIC DIAGNOSIS

- I can see no cause for the clinical sign

REFERRING VET

Dr. White
 Absence of an ileus obstruction as a cause for the diarrhea unlikely. Abdominal ultrasound is recommended to assess wall thickness and layering of the entire GIT as well as the lymph nodes. Full biochemistry and hematology will help rule out infection, renal disease and pancreatitis. Treatment for food intolerance can begin straight away with an elimination diet.

INVOICE

21169

DATE

2/17/23



PATIENT

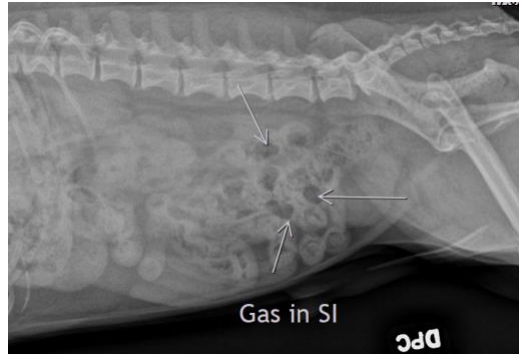
Bubby Teplyakova

SPECIES

Canine

BREED

Chihuahua



The information and recommendations provided are based on the images presented by the referring veterinarian/sonographer. No evaluation can be communicated regarding pathology that was not visible in the image/video clips provided.

SEX

Neutered Male

Thank you for this referral. If the clinical or image interpretation does not parallel your findings or if I can be of any further assistance please contact me.

AGE

6 Years 4 Months

Heike Rudolf, DVM, Dr. med. vet., DipECVDI, DVR
dr.h.rudorf@gmail.com

INTERPRETED BY

Heike Rudolf, DVM,
Dr. med. Vet.,
DipECVDI DVR

HOSPITAL NAME

DPC Veterinary
Hospital

REFERRING VET

Dr. White

INVOICE

21169

DATE

2/17/23