



PATIENT PRESENTING CLINICAL SIGNS

Tigger Walker u/s sent with labwork

SPECIES RADIOGRAPH OF THE ABDOMEN

Feline 1x RLR, 2x VD

BREED RADIOGRAPHIC FINDINGS

Ragdoll The body condition score is 6/9 with smooth alternating layers of fat and soft tissue opacity. The bony structures are within normal limits.

SEX

NM

A calabash shaped, soft tissue structure is located ventral to the ascending colon and caudal to the liver. Both compartments contain finely calcified material. The fundus contains air and is mostly obscured by the colon. On one VD view a similarly shaped structure with two gas bubble is located in the left cranial abdomen. On the other VD view two small, round air pockets and one large one are present in the cranio-central abdomen where a stack of linear, radiolucent structures is located between one gas pocket and the abdominal wall.

AGE

6

The fat between presumed stomach and spleen/left abdominal wall appears streaky on one VD view only.

INTERPRETED BY

Heike Rudolf, DVM,
Dr. med. Vet.,
DipECVDI DVR

The other abdominal structures appear physiological.

RADIOGRAPHIC DIAGNOSIS

- Calabash shaped structure in region of stomach
- Localized streaky appearance of abdominal fat

HOSPITAL NAME

Yorkville Animal
Hospital

INTERPRETATION OF THE FINDINGS & FURTHER RECOMMENDATIONS

The changes appear to be centered on the stomach and suggest wall thickening and distension. Abdominal ultrasound or a Barium meal will help clarify the anatomical relationship of the gas bubbles to rule out a tumor or outflow obstruction. The localized streakiness of the fat could be due to pancreatitis or may just represent superimposed streaky fur. Depending on the clinical signs, pancreatic enzymes should be checked.

REFERRING VET

Dr. Palumbo

INVOICE

50353

DATE

2-17-22



PATIENT

Tigger Walker

SPECIES

Feline

BREED

Ragdoll

SEX

NM

AGE

6

INTERPRETED BY

Heike Rudorf, DVM,
Dr. med. Vet.,
DipECVDI DVR

HOSPITAL NAME

Yorkville Animal
Hospital

REFERRING VET

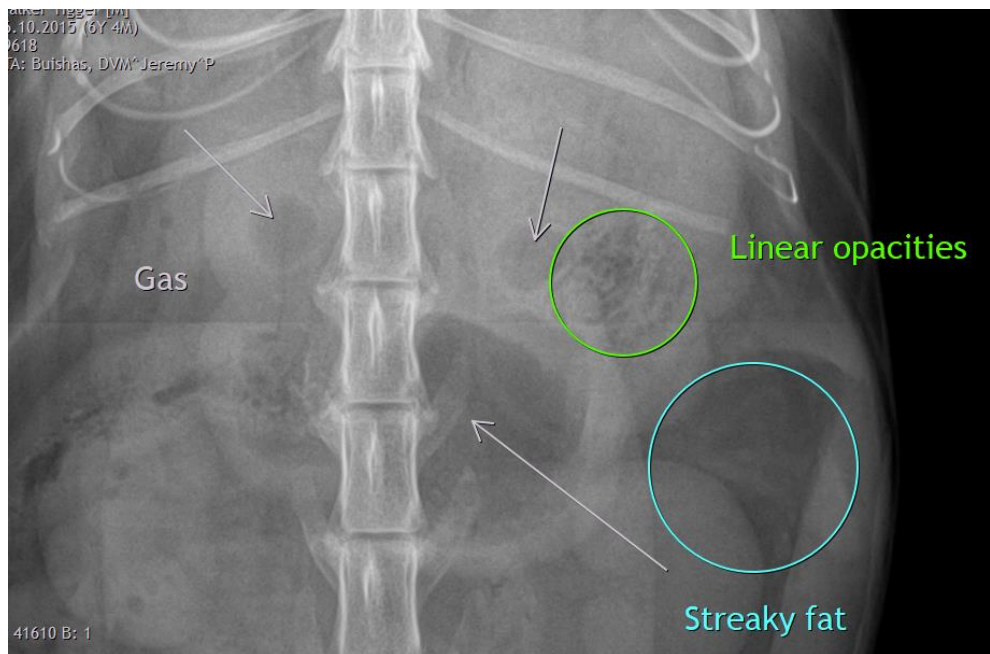
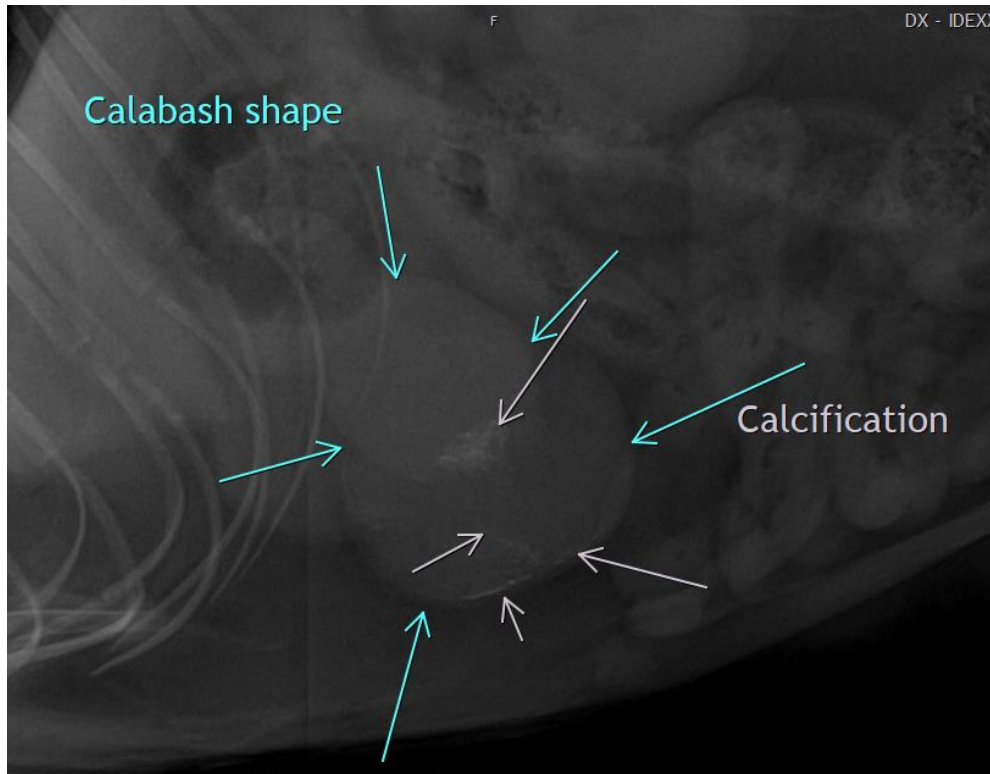
Dr. Palumbo

INVOICE

50353

DATE

2-17-22





PATIENT

Tigger Walker

The information and recommendations provided are based on the images presented by the referring veterinarian/sonographer. No evaluation can be communicated regarding pathology that was not visible in the image/video clips provided.

SPECIES

Feline

Thank you for this referral. If the clinical or image interpretation does not parallel your findings or if I can be of any further assistance please contact me.

BREED

Ragdoll

Heike Rudorf, DVM, Dr. med. vet., DipECVDI, DVR
Dr.H.Rudorf@gmail.com

SEX

NM

AGE

6

INTERPRETED BY

Heike Rudorf, DVM,
Dr. med. Vet.,
DipECVDI DVR

HOSPITAL NAME

Yorkville Animal
Hospital

REFERRING VET

Dr. Palumbo

INVOICE

50353

DATE

2-17-22