



PATIENT

Otto Riley

PRESENTING CLINICAL SIGNS

Hx of suspected aspiration pneumonia seen at ER. 4 and 6 week recheck rads included
Abnormal PE/Chem/CBC/UA Results: PE unremarkable Doing very well at home. Minimal cough

SPECIES

Canine

RADIOGRAPH OF THE THORAX

31.01.2022: R and LLR, 5x VD/DV
17.02.2022: RLR, LLR, VD

BREED

Golden Retr

RADIOGRAPHIC FINDINGS

The body condition score is 6/9 with smooth alternating layers of fat and soft tissue opacity.

SEX

The bony structures appear physiological.

MN

The lungs are in contact with the thoracic boundaries and the tips are pointed. In right lateral recumbency a linear, interstitial pattern is present in the lobes cranio-ventral to the heart border on both dates; on the left lateral recumbent views a similar opacity is present between caudal heart border and diaphragm. This is not obvious on the VD views.

AGE

6

The cranial mediastinum is of physiological size and opacity. The trachea diverges from the thoracic vertebrae and the carina is located at T6.

INTERPRETED BY

Heike Rudolf, DVM,
Dr. med. Vet.,
DipECVDDI DVR

The cardiac silhouette is slightly raised from the sternum by fat and occupies 75% of the chest height and 3 intercostal spaces. No chamber or outflow tract enlargement is evident.

RADIOGRAPHIC DIAGNOSIS

HOSPITAL NAME

Torch Lake
Veterinary Clinic

- Interstitial patter, localized

INTERPRETATION OF THE FINDINGS & FURTHER RECOMMENDATIONS

REFERRING VET

Adrienne Waffle

An interstitial pattern can be an artefact due to poor re-inflation of the uppermost lung in addition to surrounding fat which causes attenuation. Alternatively, it may represent a true infiltrate and in this case, interstitial pneumonia would be likely. Because the dog is otherwise well, either it is a true artefact, or an equilibrium has been reached with which the dog can cope and observation by the owner should be sufficient. Should the original films be available, comparison of the current location of the pattern with the original infiltrate is recommended.

INVOICE

50351

DATE

2-17-22



PATIENT

Otto Riley

SPECIES

Canine

BREED

Golden Retr

SEX

MN

AGE

6

INTERPRETED BY

Heike Rudolf, DVM,
Dr. med. Vet.,
DipECVDI DVR

HOSPITAL NAME

Torch Lake
Veterinary Clinic

REFERRING VET

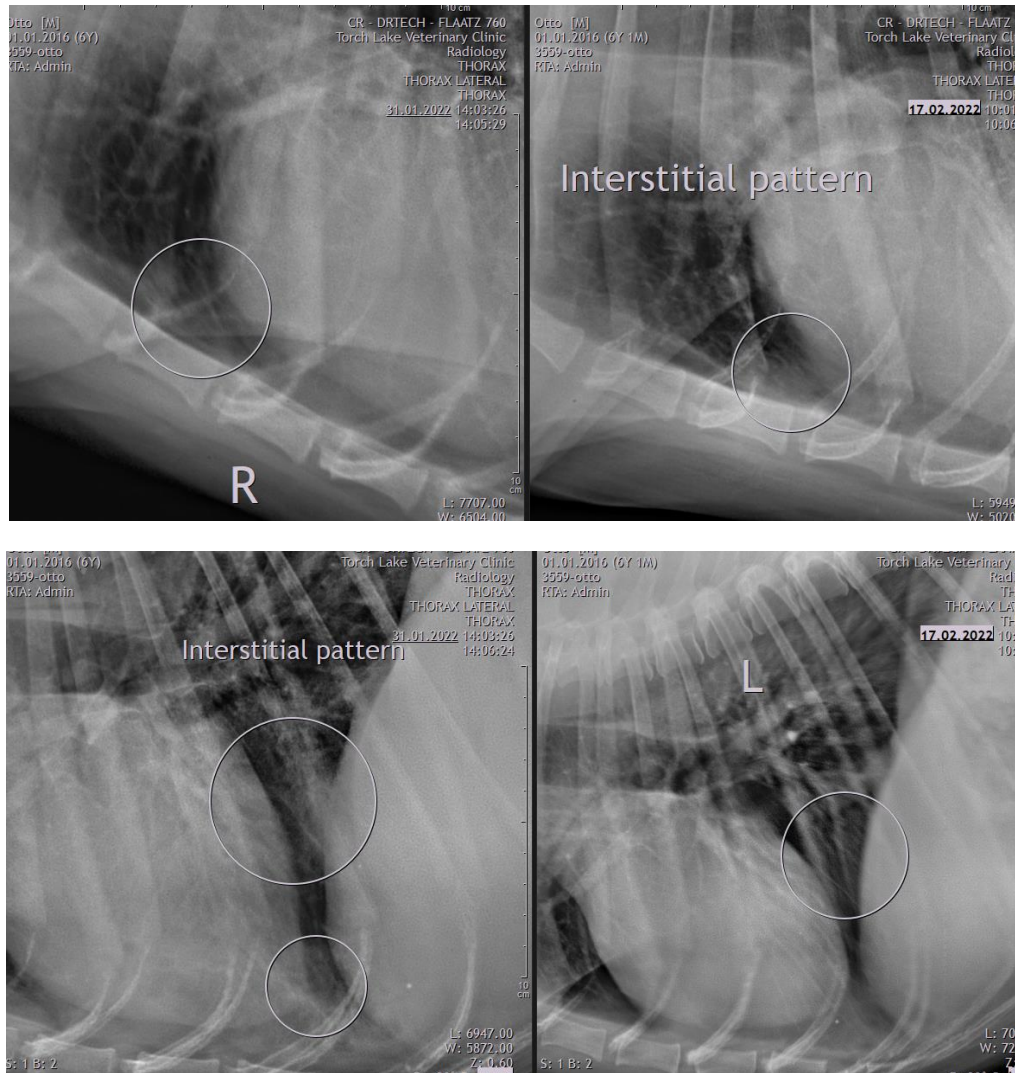
Adrienne Waffle

INVOICE

50351

DATE

2-17-22



The information and recommendations provided are based on the images presented by the referring veterinarian/sonographer. No evaluation can be communicated regarding pathology that was not visible in the image/video clips provided.

Thank you for this referral. If the clinical or image interpretation does not parallel your findings or if I can be of any further assistance please contact me.

Heike Rudolf, DVM, Dr. med. vet., DipECVDI, DVR
Dr.H.Rudorf@gmail.com