

**PATIENT**

Flap Jack Davis

PRESENTING CLINICAL SIGNS

hx of heart murmur for many years.

SPECIES

Canine

RADIOGRAPH OF THE THORAX

RLR, LLR, VD

BREED

Basset Hound

The body condition score is 6/9 with smooth alternating layers of fat and soft tissue opacity.

Ventral spondylosis is present T9-11.

SEX

Neutered Male

The lungs are in contact with the thoracic boundaries and the tips are pointed. The lobar vessels are clearly visible to the tertiary branches. The bronchial tree is thin walled and tapers uniformly towards the periphery. Pin head sized mineral structures are evenly distributed throughout the thorax.

AGE

11 Years

The cranial mediastinum is of physiological size and opacity. The trachea runs parallel to the thoracic vertebrae and dips at the carina.

The cardiac silhouette occupies 90% of the chest height and 3.5 intercostal spaces (VHS 10.5). The caudal heart border is straight and on the VD view, the tip of the heart is in close contact with the left crus of the diaphragm. An obvious atrial or outflow tract enlargement is not evident, and the pulmonary vasculature is of physiological size.

INTERPRETED BY

Heike Rudolf, DVM,
Dr. med. Vet.,
DipECVDDI DVR

RADIOGRAPHIC DIAGNOSIS

- Straight caudal heart border
- I can see no pulmonary metastases

HOSPITAL NAME

Pinebrook Animal
Hospital

- Incidental findings
- Pulmonary osteomata
 - Spondylosis

REFERRING VET

Dr. Allie Martin

INTERPRETATION OF THE FINDINGS & FURTHER RECOMMENDATIONS

A straight caudal heart border is usually associated with left ventricular enlargement. However, without left atrial enlargement it is difficult to be sure of its significance. Because the heart murmur has been present for many years, I would have expected to see more changes if it were due to mitral valve disease or cardiomyopathy. Since echocardiography is not an option for the owner, I suggest further monitoring of the heart with auscultation and making the owner aware of clinical signs associated with pulmonary edema.

INVOICE

2-17-22

DATE



PATIENT

Flap Jack Davis

SPECIES

Canine

BREED

Basset Hound

SEX

Neutered Male

AGE

11 Years

INTERPRETED BY

Heike Rudolf, DVM,
Dr. med. Vet.,
DipECVDI DVR

HOSPITAL NAME

Pinebrook Animal
Hospital

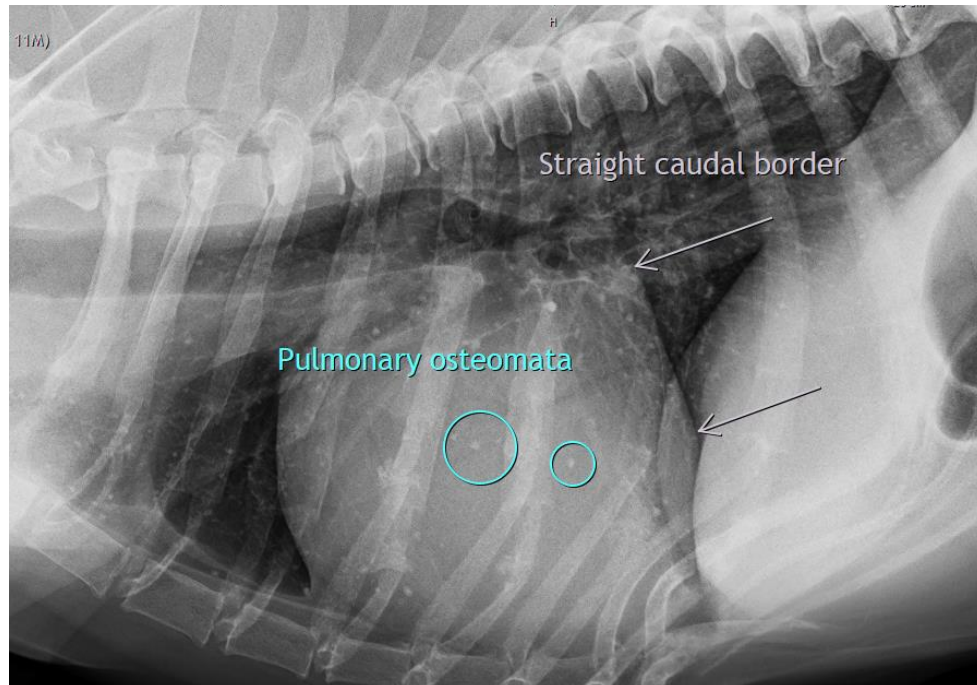
REFERRING VET

Dr. Allie Martin

INVOICE

2-17-22

DATE



The information and recommendations provided are based on the images presented by the referring veterinarian/sonographer. No evaluation can be communicated regarding pathology that was not visible in the image/video clips provided.

Thank you for this referral. If the clinical or image interpretation does not parallel your findings or if I can be of any further assistance please contact me.

Heike Rudolf, DVM, Dr. med. vet., DipECVDI, DVR
Dr.H.Rudorf@gmail.com