



PATIENT

Bentley Dyer

SPECIES

Canine

BREED

Doberman Pinscher
Mix

SEX

Neutered Male

AGE

1 Year 10 Months

WEIGHT

39.7 Pounds

INTERPRETED BY

Heike Rudorf, DVM, Dr.
med. Vet., DipECVDI
DVR

IMAGING PERFORMED BY

Gianni

HOSPITAL NAME

DPC Veterinary
Hospital

REFERRING VET

Dr. Feldt

INVOICE

35827

DATE

2/13/26

PRESENTING CLINICAL SIGNS

History: P PRESENTED FOR ANNUAL EXAM ON 1/20/26 TESTED POSITIVE FOR HEARTWORM
Abnormal PE/Chem/CBC/UA Results: Cardiovascular/Respiratory: No murmur, lungs clear

RADIOGRAPHIC STUDY OF THE THORAX

The body condition score is 6/9 with little s.c. fat.

The bony structures appear physiological.

The cranial mediastinum is of physiologic size and opacity. The trachea diverges from the thoracic vertebrae, and the carina is located level with T5/6.

The degree of pulmonary expansion is fair to good.

The lung lobes are well aerated and extend to the thoracic boundaries. Pulmonary vessels are well outlined to the tertiary branches and have a physiological size. The bronchial tree is thin walled and tapers towards the periphery.

The cardiac silhouette occupies 75% of the chest height and 2.5 intercostal spaces (VHS=9.5). A small bulge is visible at 2 o'clock.

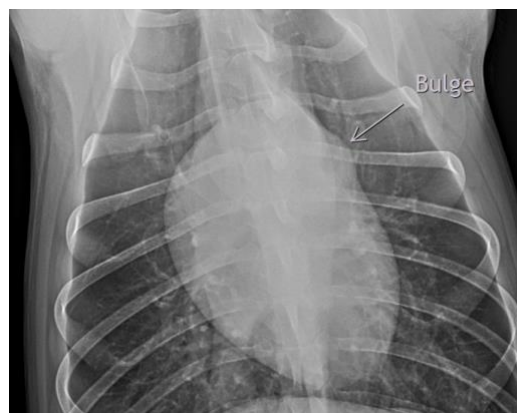The stomach is distended with dry food pebbles.

RADIOGRAPHIC DIAGNOSIS

- Bulge pulmonary artery segment, mild

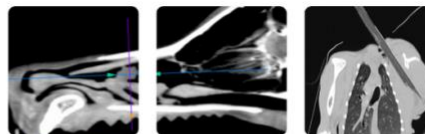
INTERPRETATION OF THE FINDINGS & FURTHER RECOMMENDATIONS

I can see no evidence of vascular changes. The bulge at the main pulmonary artery could be due to mild pulmonic stenosis, pulmonary hypertension, worms with blood flow alteration or may represent a physiological variation. Echocardiography is recommended.



The information and recommendations provided are based on the images presented by the referring veterinarian/sonographer. No evaluation can be communicated regarding pathology that was not visible in the image/video clips provided.

Thank you for this referral. If the clinical or image interpretation does not parallel your findings or if I



PATIENT

Bentley Dyer

SPECIES

Canine

BREED

Doberman Pinscher

Mix

SEX

Neutered Male

AGE

1 Year 10 Months

WEIGHT

39.7 Pounds

INTERPRETED BY

Heike Rudorf, DVM, Dr.

med. Vet., DipECVDI

DVR

**IMAGING
PERFORMED BY**

Gianni

HOSPITAL NAME

DPC Veterinary

Hospital

REFERRING VET

Dr. Feldt

INVOICE

35827

DATE

2/13/26

can be of any further assistance, please contact me.

Heike Rudorf, DVM, Dr. med. vet., DipECVDI, DVR

info@sonopath.com