



PATIENT PRESENTING CLINICAL SIGNS

Miley Wondrack History: Began vomiting (black color vomitus) and anorexia 3 days ago, lethargic and febrile.
 Abnormal PE/Chem/CBC/UA Results: elevated Liver enzymes (vaccinated against Lepto)
 Total # of Files Uploaded: 1

SPECIES RADIOGRAPHIC STUDY OF THE ABDOMEN

Canine The soft tissues dorsal to the thoracic spinous processes shows multiple small, round to oval opacities.

BREED The disc space L2/3 is decreased, and spondylosis is present.

Maltipoo The abdominal detail between caudal liver lobe and spleen is reduced.

SEX Multiple round gas shadows of varying diameter are located in the region of the gall bladder and extend dorsally in a seemingly tubular alignment.

Spayed Female The tail of the spleen appears physiological.

AGE The other structures appear physiological.

14 Years **RADIOGRAPHIC DIAGNOSIS**

- Gas in region of ventral liver, gall bladder and biliary tree

INTERPRETED BY Incidental findings

Heike Rudolf, DVM,
 Dr. med. Vet.,
 DipECVDI DVR

- Subcutaneous nodules
- Disc disease L2/3
- Spondylosis

HOSPITAL NAME INTERPRETATION OF THE FINDINGS & FURTHER RECOMMENDATIONS

New Bridge VP Emphysematous cholecystitis can be associated with diabetes mellitus or may occur due to gas forming organisms such as Clostridium sp. which can also affect the hepatic parenchyma. A VD view or ultrasound will allow accurate localization of the gas with a view to surgery and ultrasound can also detect if a localized peritonitis is present. Once diabetes has been ruled out, surgery should be performed. However, as the dog is febrile, I suggest surgery.

REFERRING VET
 Dr. Abina Glennon

TECHNICAL COMMENTS

INVOICE Human fingers in primary beam

13883

DATE

2/11/22



PATIENT

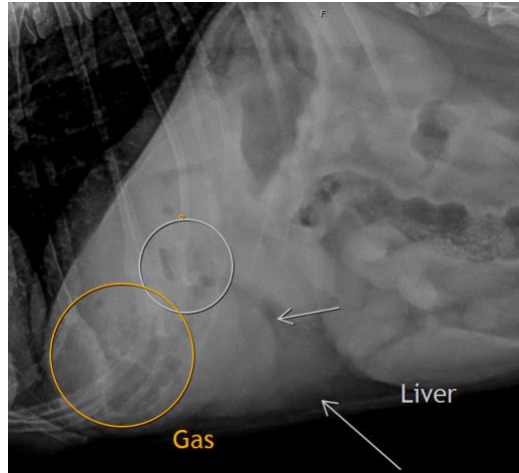
Miley Wondrack

SPECIES

Canine

BREED

Maltipoo



SEX

Spayed Female

The information and recommendations provided are based on the images presented by the referring veterinarian/sonographer. No evaluation can be communicated regarding pathology that was not visible in the image/video clips provided.

AGE

14 Years

Thank you for this referral. If the clinical or image interpretation does not parallel your findings or if I can be of any further assistance please contact me.

Heike Rudolf, DVM, Dr. med. vet., DipECVDI, DVR
dr.h.rudorf@gmail.com

INTERPRETED BY

Heike Rudolf, DVM,
Dr. med. Vet.,
DipECVDI DVR

HOSPITAL NAME

New Bridge VP

REFERRING VET

Dr. Abina Glennon

INVOICE

13883

DATE

2/11/22