



PATIENT PRESENTING CLINICAL SIGNS

Maggie Lutman History: Presented for 3 days of intermittent vomiting following a boarding stay. O reports vomiting mostly liquid/bile, randomly throughout the day and/or night. P less interested in food, but still eating a bit and will take treats. Mildly lethargic. O also reports less urination.

SPECIES

Canine Abnormal PE/Chem/CBC/UA Results: CBC/Chem/UA pending In house cPL - 60 (WNL) TPR WNL, no specific areas of concern on abdominal palpation

RADIOGRAPHIC STUDY OF THE ABDOMEN

BREED

Border Collie The body condition score (BCS) is 6/9 with smooth alternating layers of fat and soft tissue opacity. The bony structures are within normal limits.

SEX

Spayed Female The abdominal detail is in line with the BCS; diaphragm and abdominal wall are intact. The liver is located within the costal arch and the caudo-ventral lobe is pointed.

AGE

1.3 Years The spleen appears physiological. The stomach contains a mixture of fluid and air. On the VD view the small intestinal loops in the right caudal abdomen appear stacked; in left lateral recumbency two small intestinal loops contain gas and are placed one on top of the other. Colon and rectum contain a moderate amount of fecal matter.

INTERPRETED BY

Heike Rudolf, DVM, Dr. med. Vet., DipECVDI DVR Both renal shadows appear to be of physiological size; the bladder is located in the abdominal cavity and contains a moderate amount of homogeneous fluid opacity. The sublumbar region appears physiological.

HOSPITAL NAME

RADIOGRAPHIC DIAGNOSIS

- Mild small intestinal stacking

INTERPRETATION OF THE FINDINGS & FURTHER RECOMMENDATIONS

REFERRING VET

Dr. Ashman The small intestinal distribution is suggestive of a linear foreign body, but enteritis can also lead to this appearance. Abdominal ultrasound is recommended to assess the gastro-intestinal tract for foreign material. Stomach and colon should be empty to optimize visibility. Alternatively, Barium can be given and the 12 and 24 hour films will outline the foreign body.

INVOICE

13894

DATE

2/11/22



PATIENT

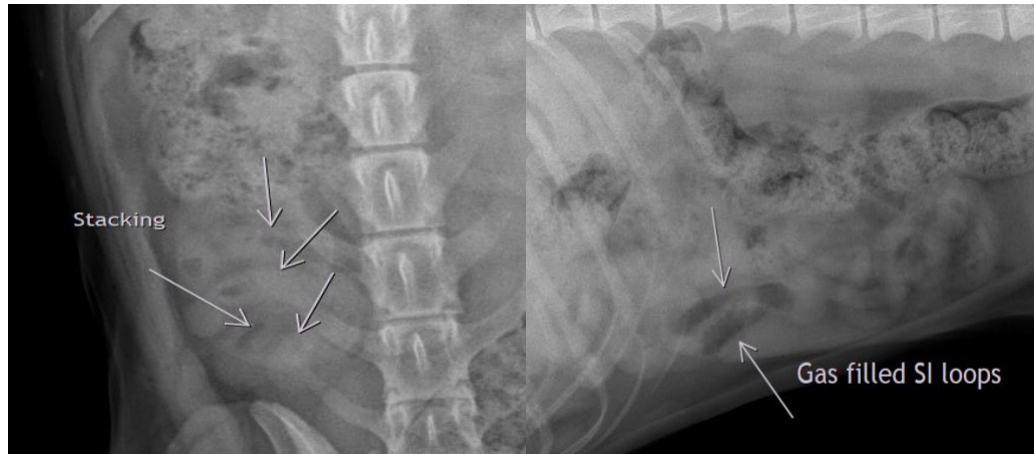
Maggie Lutman

SPECIES

Canine

BREED

Border Collie



SEX

Spayed Female

The information and recommendations provided are based on the images presented by the referring veterinarian/sonographer. No evaluation can be communicated regarding pathology that was not visible in the image/video clips provided.

AGE

1.3 Years

Thank you for this referral. If the clinical or image interpretation does not parallel your findings or if I can be of any further assistance please contact me.

Heike Rudorf, DVM, Dr. med. vet., DipECVDI, DVR
dr.h.rudorf@gmail.com

INTERPRETED BY

Heike Rudorf, DVM,
Dr. med. Vet.,
DipECVDI DVR

HOSPITAL NAME

Boca Park AH

REFERRING VET

Dr. Ashman

INVOICE

13894

DATE

2/11/22