



**PATIENT PRESENTING CLINICAL SIGNS**

Roxy Lee History: Acute vomiting and bloody diarrhea P ate a plant from the backyard yesterday. Assessment: Hematemesis and hematochezia-r/o infectious, inflammatory, toxin, ingestion of irritant, obstruction, metabolic or endocrine cause

**SPECIES RADIOGRAPHIC STUDY OF THE ABDOMEN**

Canine The body condition score is 6/9 with smooth alternating layers of fat and soft tissue opacity.

The bony structures are within normal limits.

**BREED**

American Bully The abdominal detail is good; diaphragm and abdominal wall are intact.

The liver is located within the costal arch and the caudo-ventral lobe is pointed.

**SEX**

Spayed Female The tail of the spleen extends along the ventral abdominal wall level with T13 and L6.

The stomach contains a moderate amount of air; distribution and size of the small intestinal loops appear physiological; most of them contain gas. The colon contains a very small amount of unformed feces.

**AGE**

1 Year The left renal shadow has a physiological size, shape and opacity; the right is obscured by intestinal loops. The bladder is located in the abdominal cavity and contains a moderate amount of homogeneous fluid opacity.

**INTERPRETED BY**

The sublumbar region appears physiological.

Heike Rudolf, DVM,  
Dr. med. Vet.,  
DipECVDI DVR

**RADIOGRAPHIC DIAGNOSIS**

- Splenomegaly

**HOSPITAL NAME**

DTLAvets

**INTERPRETATION OF THE FINDINGS & FURTHER RECOMMENDATIONS**

I can see no obvious foreign object or intestinal obstruction. Splenomegaly may be secondary to sedation or part of immune-mediated hemolytic anemia (IMHA). Hematology and full biochemistry are necessary to rule out pancreatitis and IMHA. Should conservative treatment fail to improve the clinical signs, abdominal ultrasound is recommended to assess splenic architecture and gastro-intestinal wall layering and -thickness.

**REFERRING VET**

Dr. Amini

**INVOICE**

21069

**DATE**

2/10/23



**PATIENT**

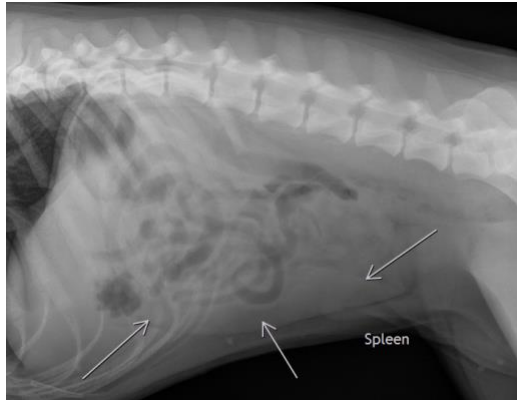
Roxy Lee

**SPECIES**

Canine

**BREED**

American Bully



**SEX**

Spayed Female

**AGE**

1 Year

**The information and recommendations provided are based on the images presented by the referring veterinarian/sonographer. No evaluation can be communicated regarding pathology that was not visible in the image/video clips provided.**

Thank you for this referral. If the clinical or image interpretation does not parallel your findings or if I can be of any further assistance please contact me.

**Heike Rudorf, DVM, Dr. med. vet., DipECVDI, DVR**  
dr.h.rudorf@gmail.com

**INTERPRETED BY**

Heike Rudorf, DVM,  
Dr. med. Vet.,  
DipECVDI DVR

**HOSPITAL NAME**

DTLAvets

**REFERRING VET**

Dr. Amini

**INVOICE**

21069

**DATE**

2/10/23