



PATIENT PRESENTING CLINICAL SIGNS

PATIENT Harvey Chapman
PRESENTING CLINICAL SIGNS History: Coughing for the last 3-4 days, progressively worsening, worsens with activity and with collar. No exposure history (i.e., no dog parks, boarding, swimming, etc.). On PE no obvious abnormalities noted, dry soft cough on and off throughout exam.

SPECIES RADIOGRAPHIC STUDY OF THE THORAX

SPECIES Canine
 The body condition score is 8/9 with smooth alternating layers of fat and soft tissue opacity.
 The bony structures appear physiological.

BREED Golden Retriever
 The lungs are in contact with the thoracic boundaries and the tips are pointed. The left caudo-ventral lobe shows air-bronchograms and the right cranial lobe a more localized increase in opacity. On the VD view the right caudal lobe, level with rib 6, shows a localized rounded increased opacity and the cranial lobe appears more increased in opacity. The degree of pulmonary expansion is fair at best.

SEX Neutered Male
 The cranial mediastinum is of physiological size and opacity. The trachea diverges from the thoracic vertebrae and dips at the carina. Air is present in the esophagus between C6 and T8.

The cardiac silhouette occupies 75% of the chest height and 3.5 intercostal spaces. No chamber or outflow tract enlargement is evident.

AGE RADIOGRAPHIC DIAGNOSIS

- AGE** 2
- Ventral alveolar infiltrate left more than right
 - Air in esophagus

INTERPRETED BY INTERPRETATION OF THE FINDINGS & FURTHER RECOMMENDATIONS

INTERPRETED BY Heike Rudorf, DVM, Dr. med. Vet., DipECVDI DVR
INTERPRETATION OF THE FINDINGS & FURTHER RECOMMENDATIONS The changes are compatible with aspiration pneumonia due to megaesophagus or esophageal motility disorder. Conservative management for megaesophagus should be initiated and antibiotics given. In case the infiltrate does not respond to the chosen antibiotics, trachea-bronchoscopy with BAL is recommended. The larynx should be checked for paralysis during induction, as this is a common disease in older, Retriever type dogs.

HOSPITAL NAME

All Creatures AH
 Stuart

REFERRING VET

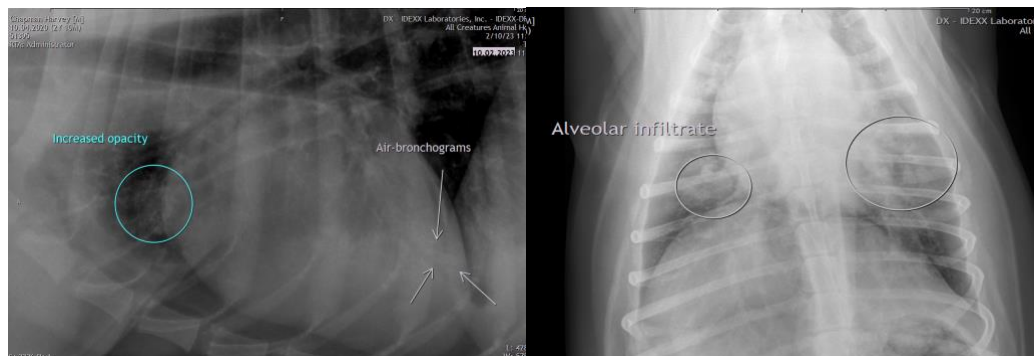
Dr. Jessica Collier

INVOICE

21066

DATE

2/10/23





PATIENT

Harvey Chapman

The information and recommendations provided are based on the images presented by the referring veterinarian/sonographer. No evaluation can be communicated regarding pathology that was not visible in the image/video clips provided.

SPECIES

Canine

Thank you for this referral. If the clinical or image interpretation does not parallel your findings or if I can be of any further assistance please contact me.

Heike Rudolf, DVM, Dr. med. vet., DipECVDI, DVR
dr.h.rudorf@gmail.com

BREED

Golden Retriever

SEX

Neutered Male

AGE

2

INTERPRETED BY

Heike Rudolf, DVM,
Dr. med. Vet.,
DipECVDI DVR

HOSPITAL NAME

All Creatures AH
Stuart

REFERRING VET

Dr. Jessica Collier

INVOICE

21066

DATE

2/10/23